

## Literature Review

## Various Tamponade in Surgery for Retinal Detachment Associated with Proliferative Vitreoretinopathy

Faraby Martha, Andi A Victor, Elvioza, Ari Djatikusumo, Gitalisa A Andayani, Anggun R Yudantha  
Department of Ophthalmology, Faculty of Medicine, Indonesia University  
Cipto Mangunkusumo Hospital, Jakarta

### ABSTRACT

**Background:** To review the literature and report relative efficacy and safety of various tamponade agents used with surgery for rhegmatogenous retinal detachment (RRD) complicated by proliferative vitreoretinopathy (PVR) regarding functional success rate, anatomical success rate, and adverse effects.

**Methods:** We searched articles from PubMed and Clinical Key database starting from the year of 1990 to November 2014. Information needed from all articles were extracted into data extraction sheet. We reviewed the efficacy of both tamponade agents regarding the postoperative visual acuity, macular attachment, and adverse effect.

**Results:** Eight articles were included after fulfilling inclusion and exclusion criteria. Our analysis showed all studies shows an increasing visual acuity and percentage of macular attachment postoperatively of all type tamponade agents. Functional and anatomical success rate of Sulfur hexafluoride gas (SF6) was high in study with PVR stage B or less (94-98%). In patient with complex or recurrent RD associated with PVR, silicone oil had a better functional success (51% vs 32.5%) and better anatomical success (80% vs 60%) than SF6 gas. The anatomical success rate also higher in C3F8 than in SF6 group (73.9% vs 57.5% respectively). Functional and anatomical success rate of HSO as tamponade was high in patients with a severe PVR located mainly in the inferior quadrants (92.3%).

**Conclusion:** As tamponade agents, C3F8 and silicone oil appear to have more visual and anatomic advantages over SF6 in participants with complex or recurrent RD associated with PVR. Silicone oil was better than C3F8 gas to obtain final visual and anatomic success in patient with recurrent RD associated with higher grade PVR. Heavy silicone oil would be useful in particular cases complicated by recurrent inferior RD with PVR. Retinal redetachment, glaucoma, cataract, hypotony and keratopathy were reported in both gases and silicone group.

**Keywords:** Tamponade in retinal detachment surgery, SF6, C3F8, silicon oil, and heavy silicone oil

The retina is the light-sensing tissue in the back of the eye, and its normal function depends on its attachment to an underlying layer called the retinal pigment epithelium (RPE). Rhegmatogenous Retinal detachment (RRD), a physical separation of the retina from the RPE in the presence of a retinal break and consequent accumulation of subretinal fluid, remains

an important cause of visual loss. Retinal detachment (RD) repair is one of the most commonly performed vitreo-retinal procedures, with the annual incidence of retinal detachment in a European population estimated to be 12.05 per 100,000 population with a cumulative lifetime risk of approximately 3%. Rhegmatogenous Retinal detachment may or may not involve the

macula, but patients with macular detachment typically have more severe visual loss than patients without macular detachment.<sup>1-4</sup>

Proliferative vitreoretinopathy (PVR) is a serious complication of RRD and can lead to failure of RRD surgery. Proliferative vitreoretinopathy is the commonest cause of failure in retinal reattachment surgery, occurring in 5-10% of cases of retinal detachment and accounting for irreparable loss of vision in approximately 1000 eyes in the United States each year.<sup>5</sup> The clinical spectrum of PVR usually corresponds to the length of time of retinal detachment and also is more common in inferior retinal detachments.<sup>4</sup> The only proven therapy for RD with PVR is further surgery; where the membranes must be physically removed from the surface of the retina. In some patients surgery is initially successful but RD may recur months or years later.<sup>3,4</sup>

Vitreotomy and endotamponade is a frequent surgical choice for the treatment of RRD.<sup>6</sup> In addition, injection of a material to hold the newly attached retina in position, called a tamponade agent, is performed to reduce the rate of fluid flow through open retinal tears, which would cause recurrent RD. The major tamponade agents that are available today are various gases and silicone oils.<sup>4</sup> For primary RD, these procedures have a very high rate of successful anatomic retinal re-attachment (overall above 90%). Success rates of 72–94% are reported for primary surgeries, and to an extent preoperative findings can be used to individualize the chance of success.<sup>1</sup> The Scleral Buckling versus Primary Vitrectomy in Rhegmatogenous Retinal Detachment (SPR) study reported single operation success rates between 60% to 80%, depending on the subgroup, and 73% overall.<sup>7</sup> In Cipto Mangunkusumo hospital, Isran reported anatomical success as 78.38% using silicone oil tamponade on RRD with PVR stage C.<sup>8</sup> PVR reduces anatomical success rates and leads to poor functional results resulting also in an increase of the cost of the RD treatment.<sup>9</sup>

In the treatment of rhegmatogenous retinal detachment (RRD), intraocular tamponade provides retinal attachment to assure establishment of a chorioretinal adhesion. Tamponade is also necessary to reduce the rate of fluid flow through open retinal tears, which would cause

recurrent RD. Tamponade agents are useful in broad categories of patients with RD such as patients with primary RD, patients with complex or recurrent RD associated with PVR, RD associated with a giant retinal tear, and patients with inferior RD. Patients with complex or recurrent RD associated with PVR as focus of this review, typically treated with either gas or silicone oil.<sup>10</sup> The choice of agent depends on the location of the retina requiring support and also the desired duration of the tamponade effect. Intraocular tamponade agents can be divided into those that are self limiting and those that necessitate surgical removal. Self-limiting agents include the inert gases—air, sulfur hexafluoride (SF<sub>6</sub>), and perfluoropropane (C<sub>3</sub>F<sub>8</sub>). Agents that require removal include silicone oil, and heavy silicone oil.<sup>4</sup>

Previous study reported that the guaranteed and extended nature of silicone oil tamponade might improve the anatomical results in RRD with PVR cases, but that the ultimate visual result could be compromised by complications related to its use.<sup>11</sup> Currently, there is still variability among vitreoretinal surgeons as to the indications for using silicone oil. In Europe, silicone oil is used more readily as a primary tamponade agent than in the United States. Thus, the controversy remains as to whether one ought to use the long-acting gas or to use silicone oil. The current standard is to use silicone oil in subsequent retinal redetachment cases with PVR.<sup>4</sup>

## Problem

The various tamponade agents such as SF<sub>6</sub>, C<sub>3</sub>F<sub>8</sub>, standard silicone oil and heavy silicone oil offer different advantages and disadvantages in terms of safety and effectiveness.<sup>4</sup> Comparing of both tamponade agents what are the advantages and disadvantages of each one regarding the postoperative visual acuity, macular attachment, and adverse effect? A systematic review may assist surgeons in the selection of a tamponade agent.

## Purpose

The objective of this paper is to review the literature and report relative efficacy and safety of various tamponade agents used with surgery

for rhegmatogenous retinal detachment (RRD) complicated by proliferative vitreoretinopathy (PVR) regarding functional success rate, anatomical success rate, and adverse effects.

## MATERIALS AND METHODS

We searched articles from PubMed and Clinical Key database starting from the year of 1990 to November 2014. The search strategy was based on combinations of medical subject headings and free text word. Search terms used were “tamponade in retinal detachment surgery”, “SF6”, “C3F8”, “Silicon oil”, and “Heavy silicone oil”. Only articles published in English were included. The searches were supplemented by manually searching the bibliographies of included studies and reviews.

### Study Selection and Criteria

The inclusion criteria were all studies (prospective and retrospective studies) of level IV or higher,

which reported retinal detachment patients who were underwent surgical repair of RD and agents used as tamponade in the treatment of RD associated with PVR, such as sulfur hexafluoride (SF6), perfluoropropane (C3F8), and silicon oil, as well as investigational agents such as heavy silicone oil. The outcomes that should be reported from each study were visual acuity (VA), macular attachment and adverse effect. Exclusion criteria were studies of eyes with retinal vascular diseases and inflammatory diseases, Retinal detachment (RD) caused by tractional RD or exudative RD, RRD without PVR, studies below level IV of Evidence-Based Medicine (EBM) level of evidence, the full text could not be obtained and full text was not provided in English.

All selected articles were then rated based on the level of evidence developed by Oxford Centre for EBM levels of evidence. Abstracts were then screened based on the inclusion and exclusion criteria.

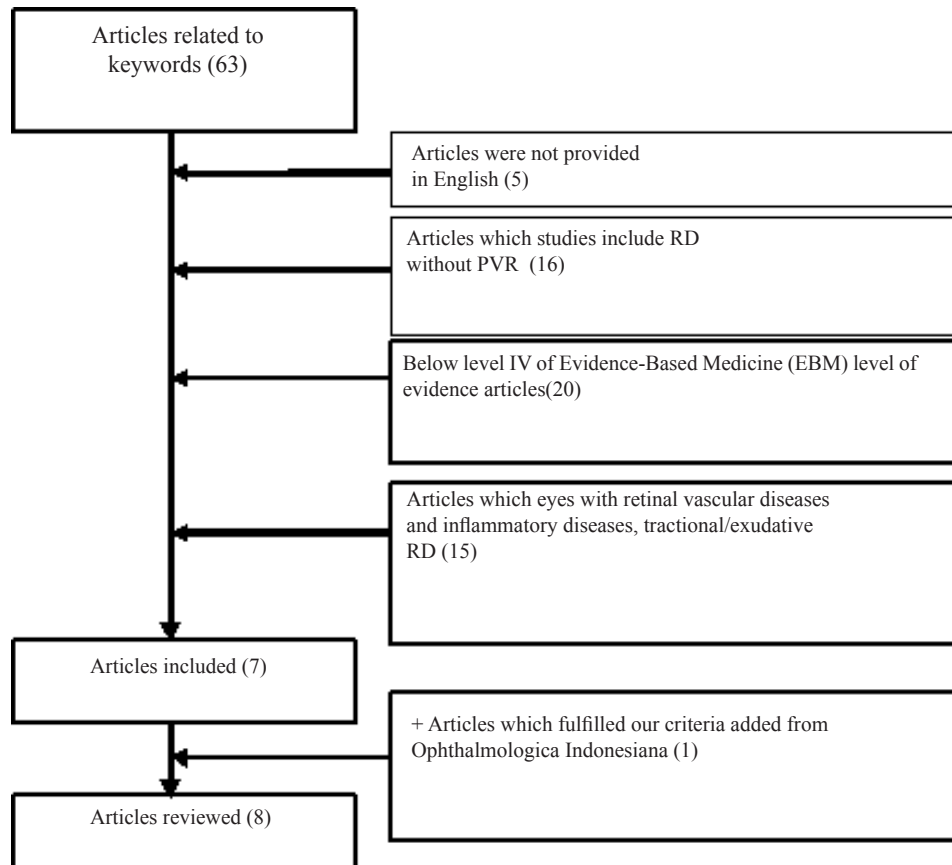


Fig 1. The schematic diagram of article flow

**Table 1.** Level of evidence for primary research question: criteria from the Center of Evidence-Based Medicine, Oxford, United Kingdom for treatment benefits<sup>12</sup>

Level	Therapy Study
I	Systematic reviews (with homogeneity) of randomized controlled trials
II	Randomized controlled trials or observational study with dramatic effect
III	Non-randomized controlled cohort/ follow-up study Case-series, case-control studies, or historically
IV	controlled studies
V	Mechanism-based reasoning

### Data Processing and Presentation

We extracted information from the full articles into data extraction sheet. Extracted information included number of treated eyes, agents used as tamponade, and mean follow up time after surgery. We then reviewed the efficacy and the adverse effect following surgical repair of RD and uses of various tamponade agents.

### RESULTS

Our search strategies identified a total of 63 articles related to the search terms. Five articles were excluded due to the full text was not provided in English. We excluded 16 articles because the studies include RRD without PVR. We also excluded 15 studies of eyes with retinal vascular diseases and inflammatory diseases, retinal detachment caused by tractional RD or exudative RD. We also excluded 20 trials below level IV of Evidence-Based Medicine (EBM) level of evidence. We evaluated the articles and found 7 articles which comparing various tamponade agents in surgery for retinal detachment (RD) complicated by proliferative vitreoretinopathy (PVR). We added one articles which fulfilled our criteria from *Ophthalmologica Indonesiana*.

Characteristic data of the reviewed material are presented in table 2. Reviewed articles were published between 1992-2013. The studies are categorized in the level evidence II-IV. Based on the study design, four study are a randomized controlled trial while the others were retrospective, prospective studies with level of evidence III-IV. Focus in the article reviewed are comparing gas and silicone oil in

two study, comparing silicone oil with HSO in one study, effectiveness of SF<sub>6</sub>, SO, and HSO alone in 5 studies. The total eyes in each article varied from 26-138 eyes and the duration of follow-up after surgery range from 1-36 months.

Study in tamponade for retinal detachment associated with PVR vary in the method and subjects. Jousen<sup>15</sup> study/The Heavy Silicone Oil Study (HSO study) was initiated to investigate whether a specific tamponade with HSO is able to reduce the rate of proliferative vitreoretinopathy (PVR) in inferior retinal tear or inferior PVR with inferiorly and posteriorly located PVR grade C-A6. The Silicone Study<sup>11,16</sup> was designed to evaluate the benefits and risks of using a long-acting gas bubble or silicone oil as an intraocular tamponade following vitrectomy in eyes with severe PVR grade C3, D1, D2, D3. Two studies was reported, In the first phase of the trial, sulfur hexafluoride (SF<sub>6</sub>) gas, and in the second (later) phase of the trial, perfluoropropane gas was used in eyes randomized to gas. Silicone study report 1 evaluate 101 eyes with rhegmatogenous retinal detachment and severe (with a classification of at least C-3) proliferative vitreoretinopathy treated with vitrectomy and randomized to either a mixture of 20% sulfur hexafluoride gas and air or to 1000 centistokes of silicone oil.<sup>11</sup> Silicone study report 2 compare 14% C<sub>3</sub>F<sub>8</sub> gas with 1000-centistoke silicone oil for use as an extended intraocular tamponade in eyes undergoing vitrectomy for retinal detachment complicated by severe PVR.<sup>16</sup> Brazitikos<sup>17</sup> studied the anatomical and functional outcome of pars plana vitrectomy (PPV) with injection of 20% SF<sub>6</sub> in the treatment of primary rhegmatogenous pseudophakic retinal detachment (RD) with PVR stage B or less. Tognetto et al<sup>18</sup> evaluate the effectiveness and safety of a heavy silicone oil (HSO) tamponade for complicated retinal detachment (RD) surgery with PVR involving the inferior quadrants grade greater than CP-6 and greater than CA-6. This tamponade was obtained by mixing 30% by volume perfluorohexyloctane and 70% by volume silicone oil, 1000 millipascal-seconds (polydimethylsiloxane 1000).<sup>18</sup> Goto et al<sup>19</sup> compare the anatomic success between repair of rhegmatogenous retinal detachment (RRD)



for superior breaks and repair of RRD for inferior breaks with PVR grade A or B, by performing primary vitrectomy and using 20% sulphur hexafluoride gas tamponade. Duan et al<sup>20</sup> observe the complications after heavy silicone oil (HSO) tamponade in complicated retinal detachment with PVR grade B,C1,C2,C3, D1,D2. Isran evaluate anatomical success, functional success, and complication of PPV with SO tamponade for treating RRD with PVR grade C.<sup>8</sup>

The aim of this literature review is to find out the efficacy and safety of various tamponade agents used with surgery for rhegmatogenous retinal detachment (RRD) complicated by proliferative vitreoretinopathy (PVR). Efficacy is determined by participants achieving 5/200 (LogMAR +1.6) or better visual acuity (functional success rate) and/or macular attachment (anatomical success rate). Safety is determined by the rate of adverse effect of each tamponade agents. Table 3,4 and 5 summarized those findings.

Table 3 shows visual acuity preoperatively and at the last follow up as percentage of functional success rate. All studies shows an increasing visual acuity postoperatively of all type tamponade agents. Two studies reported the changes in visual acuity at last follow up as mean logMAR, so the functional success rate as this review criteria cannot be assessed. Figure 2 shows functional success rate from various tamponade. Functional success rate of Sulfur hexafluoride gas (SF6) was 32.5% reported by Silicone study report 111 and 98% reported by Brazitikos et al<sup>17</sup>. Functional success rate of perfluoropropane gas (C3F8) was 40.5% reported by Silicone study 2<sup>16</sup>. Functional success rate of silicone oil reported as 51% and 39.6% by Silicone study 1 and 2<sup>11, 16</sup> and 21% by Isran<sup>8</sup>. Functional success rate of HSO was 92.3% reported by Tognetto et al<sup>18</sup> and 81 % reported by Duan et al<sup>20</sup>.

**Table 2.** Characteristic of the reviewed material

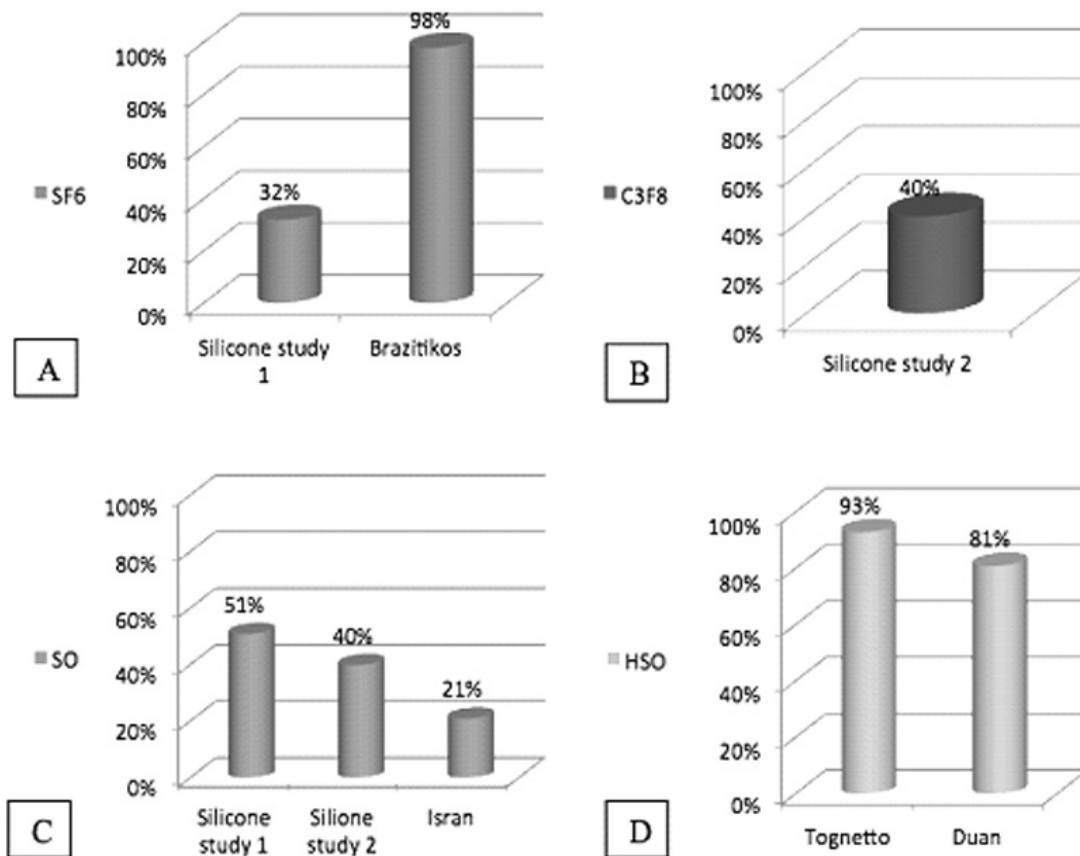
No	Author	Publication Year	Study design	Level of Evidence	Focus of study	Number of Eye Treated		Visual acuity range	PVR grade	Follow up time
						SF6/C3F8	Silicone oil/Heavy silicone oil			
1	Joussen et al (HSO study) <sup>15</sup>	2007	Prospective, multicentre, randomized, controlled, clinical trial	II	Standard silicone oil vs Heavy silicone oil	NA	47 SO 46 HSO	1.59 ± 0.83 1.82 ± 0.90	Inferiorly and posteriorly located PVR grade C-A6	12 months
2	Silicone study 1 <sup>11</sup>	1992	Unmasked, multicenter randomized controlled trial	II	Sulfur hexafluoride gas (SF6) vs Silicone oil	49 SF6	52 SO	LP- ≥5/200 ≥5/200= 5%	C3, D1,D2, D3	36 months
3	Silicone study 2 <sup>16</sup>	1992	Unmasked, multicenter randomized controlled trial	II	perfluoropropane gas (C3F8) vs Silicone oil	138 C3F8	127 SO	LP- ≥5/200 ≥5/200= 5%	C3, D1, D2, D3	36 months
4	Brazitikos et al <sup>17</sup>	2005	Prospective, randomized clinical trial	II	Sulfur hexafluoride gas (SF6)	75 SF6	NA	<20/400- 20/20 ≥5/200=60%	PVR stage B or less	12 months
5	Tognetto et al <sup>18</sup>	2005	Prospective consecutive interventional case series study	III	Effectiveness and safety of a heavy silicone oil	NA	26 HSO	HM- 20/100 ≥5/200= 57%	PVR involving the inferior quadrants with a grade greater than CP-6 and greater than CA-6	12 months
6	Goto et al <sup>19</sup>	2013	Retrospective comparative study	IV	Sulfur hexafluoride gas (SF6) in superior vs inferior breaks	82 SF6: 62 sup 20 inf	NA	0.93 ± 1.1 (sup) 0.74 ± 0.94 (inf)	PVR grade A, B	3 months
7	Duan et al <sup>20</sup>	2011	Retrospective study	IV	Heavy silicone oil	NA	33 HSO	HM- 20/100 ≥5/200= 27%	PVR grade B,C1,C2,C3, D1,D2	3- 24 months
8	Isran <sup>8</sup>	2007	Retrospective study	IV	Silicone oil	NA	37 SO	LP – 3/60 ≥5/200= 5%	PVR grade C	1 month

**Table 3.** Functional success following surgery with various tamponade

No	Author	Number of Eye Treated		Time point measurements	Visual acuity $\geq$ 5/200 Preoperative (%)		Visual acuity $\geq$ 5/200 At last FU (%)		Statistically Significancy
		SF6/C3F8	Silicone oil/ Heavy fluid		SF6/C3F8	Silicone oil/ Heavy fluid	SF6/C3F8	Silicone oil/ Heavy fluid	
1	Joussen et al (HSO study) <sup>15</sup>	NA	47 SO	12 months	NA	1.59 $\pm$ 0.83 1.82 $\pm$ 0.90	NA	1.24	P 0.3
2	Silicone study 1 <sup>11</sup>	49 SF6	52 SO	24 months	0/49 (0%)	5/52 (10%)	13/40 (32.5%)	24/47 (51%)	P<0.05
3	Silicone study 2 <sup>16</sup>	138 C3F8	127 SO	36 months	8/138 (6%)	4/127 (3%)	56/138 (40.5%)	50/126 (39.6%)	p>0.05
4	Brazitikos et al <sup>17</sup>	75 SF6	NA	12 months	45/75 (60%)	NA	74/75 (98%)	NA	NA
5	Tognetto et al <sup>18</sup>	NA	26 HSO	12 months	NA	15/26 (57%)	NA	24/26 (92.3%)	NA
6	Goto et al <sup>19</sup>	82 SF6 : 62 sup 20 inf	NA	3 months	0.93 (sup) 0.74 (inf)	NA	0.14 (sup) 0.17 (inf)	NA	P= 0.72
7	Duan et al <sup>20</sup>	NA	33 HSO	3- 24 months	NA	9/33 (27%)	NA	27/33 (81%)	P<0.05
8	Isran <sup>8</sup>	NA	37 SO	1 month	NA	2/37 (5%)	NA	8/37 (21%)	NA

**Table 4.** Anatomical success following surgery with various tamponade

No	Author	Number of Eye Treated		Time point measurements	Macular attachment Preoperative (%)		Macular attachment at last FU (%)		Statistically Significancy
		SF6/C3F8	Silicone oil/ Heavy fluid		SF6/C3F8	Silicone oil/ Heavy fluid	SF6/C3F8	Silicone oil/ Heavy fluid	
1	Joussen et al (HSO study) <sup>15</sup>	NA	47 SO	12 months	NA	NA	NA	19/47 (40.43%)	P 0.27
			46 HSO					13/47 (28.26%)	
2	Silicone study 1 <sup>11</sup>	49 SF6	52 SO	24 months	NA	NA	23/40 (57.5%)	37/47 (78.7%)	P<0.05
3	Silicone study 2 <sup>16</sup>	138 C3F8	127 SO	36 months	NA	NA	102/138 (73.9%)	93/126 (73.8%)	p>0.05
4	Brazitikos et al <sup>17</sup>	75 SF6	NA	12 months	22/75 (29%)	NA	71/75 (94%)	NA	NA
5	Tognetto et al <sup>18</sup>	NA	26 HSO	12 months	NA	NA	NA	24/26 (92.3%)	NA
6	Goto et al <sup>19</sup>	82 SF6: 62 sup 20 inf	NA	3 months	26/62 (41%) 9/20 (45%)	NA	61/62 (98%) 16/20 (80%)	NA	P<0.05
7	Duan <sup>20</sup>	NA	33 HSO	3- 24 months	NA	0/33 (0%)	NA	29/33 (87.9%)	NA
8	Isran <sup>8</sup>	NA	37 SO	1 month	NA	8/37 (21%)	NA	29/37 (78.4%)	NA



**Fig 2.** Functional success rate from various tamponade: A) Sulfur hexafluoride gas (SF6); B) Perfluoropropane gas (C3F8); C) Silicone oil (SO); and D) Heavy silicone oil (HSO)

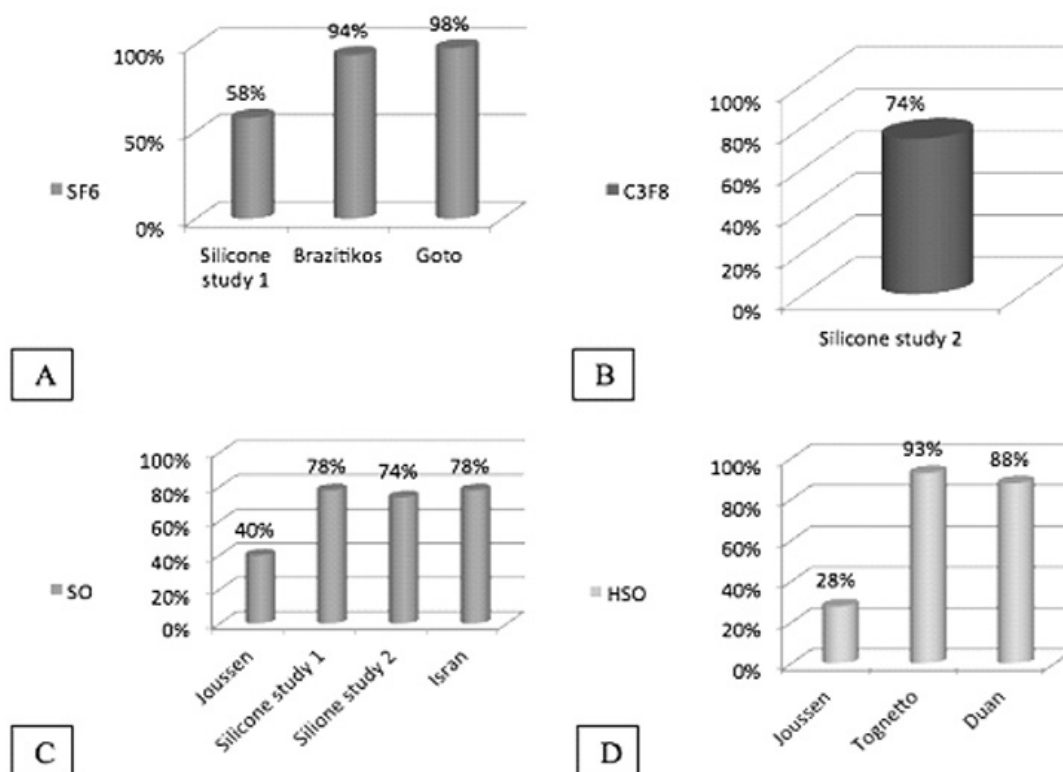
Table 4 shows macular attachment at the last follow up as percentage of anatomical success rate. All studies shows an increasing of macular attachment percentage postoperatively in all type tamponade agents. Figure 3 shows anatomical success rate from various tamponade. Anatomical success rate of Sulfur hexafluoride gas (SF6) was 94% reported by Brazitikos et al<sup>17</sup> and 98% reported by Goto et al<sup>19</sup>, meanwhile Silicone study 1<sup>11</sup> reported only 57.5% of anatomical success rate. Anatomical success rate of perfluoropropane gas (C3F8) reported by Silicone study 2<sup>16</sup> was 73.9%. Anatomical success rate of Silicone oil was 40% reported by Joussem et al<sup>15</sup>, 78.4% reported by Isran<sup>8</sup>, and 73%-78% reported by Silicone study.<sup>11,16</sup> Anatomical success rate of HSO was 28% reported by Joussem et al<sup>15</sup>, meanwhile Tognetto<sup>18</sup> and Duan<sup>20</sup> reported 87.9-92.3% eyes showed anatomical success.

Another aim of this study is to review the safety profile of various tamponade agents, which

is determined by the rate of adverse effect of each tamponade agents.

Retinal redetachment in SF6 was 5% reported by Brazitikos<sup>17</sup> and 6% reported by Goto<sup>19</sup>. Redetachment in C3F8 was 54% reported by Silicone study 2<sup>16</sup>. Retinal redetachment in silicone oil was 44% reported by Joussem et al<sup>15</sup>, 14% reported by silicone study 1<sup>11</sup>, 55% reported by Silicone study 2<sup>16</sup> and 27% reported by Isran<sup>8</sup>. Retinal redetachment in HSO tamponade was 50% reported by Joussem et al<sup>15</sup>, 7.7% by Tognetto et al<sup>18</sup>, and 12% by Duan et al<sup>20</sup>.

Glaucoma in SF6 was 2% reported by Silicone study 1. Glaucoma rate in C3F8 was 1% reported by Silicone study 2<sup>16</sup>. Glaucoma in silicone oil/HSO tamponade reported by Joussem et al<sup>15</sup> (23%), Silicone study 1<sup>11</sup> (0%) using silicone oil, Silicone study 2<sup>16</sup> (0.7%) using silicone oil, Isran<sup>8</sup> (5.4%) using silicone oil, Tognetto<sup>18</sup> (30.7%) using HSO tamponade, and Duan<sup>20</sup> (18%) using HSO tamponade.



**Fig 3.** A) Sulfur hexafluoride gas (SF6); B) Perfluoropropane gas (C3F8); C) Silicone oil (SO); and D) Heavy silicone oil (HSO)

Cataract in SF6 was 52% reported by Goto. Cataract in silicone oil/HSO tamponade reported by Joussen et al<sup>15</sup> (4%) using SO, Isran<sup>8</sup> (2.7%) using SO, Tognetto et al<sup>18</sup> (19%) using HSO, and Duan et al<sup>20</sup> (100%) using HSO tamponade.

Hypotony in gases group were reported by Silicone study<sup>11,16</sup> as 25% using SF6, 30% using C3F8. Hypotony in Silicone oil as tamponade was reported as 10% and 16% by Silicone study 1 and 2<sup>11,16</sup>.

Keratopathy in gases/silicone group were reported by Silicone study<sup>11,16</sup> as 48% using SF6, 33% using C3F8, and 21%-30% using silicone oil as tamponade. Tognetto et al<sup>18</sup> reported 0% keratopathy in HSO tamponade.

## DISCUSSION

Most recurrent RDs, and some primary RDs, are associated with varying degrees of proliferative vitreoretinopathy (PVR), or the growth of fibrous membranes (similar to scar tissue) along the surface of the retina, which leads to traction

on the retina.<sup>13</sup> RRD with PVR required complex surgery included scleral buckling, liquid silicone, and vitrectomy in combination with a variety of techniques. These include membrane dissection, intraocular gas tamponade, intraocular liquid silicone tamponade, and endolaser photocoagulation.<sup>5</sup> The purpose of retinal tamponade is to plug or block the leakage of vitreous fluid from moving into the subretinal space through a retinal break. It serves as a temporary barrier to prevent fluid in the vitreous cavity from entering retinal breaks during the formation of a retinal adhesion.<sup>21</sup> An agent with high surface tension will tightly maintain its shape and will not tend to move under the retina if it is larger than the area of the break. An agent with low specific gravity will float in the vitreous, and an agent with high specific gravity will sink inferiorly. These properties distinguish various tamponade agents from one another.<sup>4</sup>

The major tamponade agents available today are various gases and silicone oils. Currently available self limiting gases include air, sulfur hexafluoride (SF6) and perfluoropropane (C3F8).



The major advantage of gas tamponade is that the gas spontaneously dissipates, usually over several weeks.<sup>2</sup> The type and volume of injected gas depend upon the available potential space within the vitreous cavity, as well as the size of retinal break(s) and the desired duration of tamponade. In cases in which a longer tamponade effect is desired, more insoluble gases such as sulfur hexafluoride (SF6) and perfluoropropane (C3F8) are used. These possess two potentially favorable characteristics: expansile qualities if injected as pure gas, and longer duration in the eye.<sup>22</sup> Perfluoropropane (C3F8) in an isovolemic mixture of 12% has a half-life of 5 days, resulting in a presence of about 25 days in the eye. Perfluoropropane nearly quadruples in volume, reaching maximum size in about three days.<sup>2, 22</sup> SF6 has a shorter half-life of 2.5 days, correlating to a presence of about 10-14 days of gas in the eye, depending on the amount injected. SF6 doubles in volume within the eye, reaching its maximum size at about 36 hours.<sup>2, 22</sup>

The following characteristics of intraocular gases account for their efficacy in reattaching the retina: 1) Surface tension allows the gas bubble to occlude a retinal break instead of passing into the subretinal space. The surface tension of any gas is much higher than that of other substances in the eye. Once the break is occluded, the retinal pigment epithelial pump can reabsorb the subretinal fluid; 2) Buoyancy of the gas provides the force which pushes the uppermost retina back against the wall of the eye. Apposition of the retina against the retinal pigment epithelium is necessary in order that an adhesion can occur, just as two surfaces to which glue has been applied must be clamped together while the glue dries. When the gas is gone, a permanent seal remains, preventing reopening of the tear.<sup>22</sup> In most cases, the prolonged longevity of a gas bubble is a disadvantage. Air travel is contraindicated for a longer period of time with gases. The gas of choice in most cases is SF6. However surgeon use C3F8 for the case which requires an exceptionally large and long-acting gas bubble to tamponade large, widespread breaks or RRD with PVR.<sup>22</sup>

Self limiting gases such as SF6 and C3F8 resulting from to its longevity is frequently

used for tamponade in PVR surgery although it have several complications include elevated intraocular pressure and cataract formation.<sup>2</sup> C3F8 have more advantages than SO in several characteristic including: 1) absorbs spontaneously, giving temporary tamponade to retina; 2) it can control duration of tamponade from intermediate to long duration by adjusting concentration of C3F8 with air; 3) visual rehabilitation occurs more rapidly in eyes with PVR treated with gas; 4) relatively few long-term complications associated with use. On other hand C3F8 also have disadvantages including: 1) does not last long enough to provide tamponade needed for eyes with epiretinal re proliferation 6–8 weeks after surgery; 2) air travel prohibited until bubble absorbed; 3) cataract formation if prone positioning not maintained; 4) some short-term complications, such as elevated intraocular pressure; and 5) hypotony more likely post-operatively.

The various tamponade agents offer different advantages and disadvantages in terms of safety and effectiveness. Thus, the controversy remains as to whether one ought to use the long-acting gas or to use silicone oil. The choice of tamponade agent is usually made on an individual, patient-by-patient basis. Factors to be considered include efficacy and safety of each tamponade agents.

### Visual Acuity

The results in term of visual function are not easy to compare because of the different ways of expressing the results. Silicone study 1<sup>11</sup> reported that eyes randomized to silicone oil had a significantly better chance of achieving visual acuity of 5/200 or better than those randomized to SF6 gas (51% vs 32.5%), the data statistically significant at one year ( $P < 0.05$ ).<sup>11</sup> At the last follow-up examination, Silicone study 2 shows likelihoods of achieving visual acuities of 5/200 or better about the same whether eyes were randomized to C3F8 gas or silicone oil 1000 centistokes (40.5% vs 39.6%), there were no statistically differences between the two groups.<sup>16</sup> Isran<sup>8</sup> reported 21% eyes that achieving visual acuity of 5/200 or better at 1 month. The improvement of patients visual

acuity in RRD with PVR cases was depend on involvement of the macula. If the macula is off, the BCVA postoperatively will show not significant differences compare to preoperatively. In Isran study the total of patient mith macular off preoperatively was 78%. This can explain the low rate of functional success in this study. However Isran study show large portion in visual acuity that increase compare to preoperatively, which is 37.8%. Mostly RRD cases can increase the functional and anatomical success if we do a correct, accurate and fast management, and knowing the cellular and mollecular changes which connected to visual function. Several study reported the improvement of visual function in patient which had a reattachment was related to duration of ablation, the more increase duration of ablation, make the functional and anatomical success reduce. The long duration of RRD will threaten the survival of RPE, it degenerates inner and outer nuclear layer. In the next process there are atrophy and loss of ganglion retina cells. In early degeneration the ablatio is still reversible.<sup>23</sup>

Brizitikos et al<sup>17</sup> reported 98% of eyes randomized to primary PPV with 20% of SF6 tamponade achieved visual acuity 5/200 or better at the first year. However this study only include primary PPV cases with PVR stage B or less. Goto et al<sup>19</sup> reported that the functional successs rate with SF6 tamponade did not differ whether the break located superiorly or inferiorly ( $p=0.72$ ), however this result only for RRD with low grade PVR (stage B or less).

Tognetto et al<sup>18</sup> reported 92.3% of patients obtained vision equal to or better than 5/200 using HSO as tamponade. In addition, only patients with a severe PVR located mainly in the inferior quadrants were included in this study. In these cases, the conventional silicone oil does not enable the inferior quadrants to be tamponaded and often results in surgery failing. The presence of silicone oil compartmentalizes the water in the inferior part of the vitreous cavity, thus advancing PVR in quadrants where the PVR is already present. For this reason, the inferior tamponade is a crucial advantage of HSO. Joussem study<sup>15</sup> when comparing silicone with HSO, showed neither noninferiority nor

superiority ( $p=0.3$ ) was shown with regard to final acuity (functional successs rate). Thus, HSO is no better than 'normal' silicone oil.<sup>15</sup> Duan et al<sup>20</sup> reported 81% had a visual acuity of 5/200 or better in HSO tamponade. The patient has PVR grade B,C1,C2,C3, D1,D2 using the Retina Society Classification (1983). Duan et al consider that the differences in visual acuity are more likely to be related to the degree of PVR, surgical history, and preexistent macular hole/edema instead of the difference in toxicity of different tamponades.

### Macular Reattachment

Joussem study<sup>15</sup> results showed no significant difference between HSO and standard silicone oil regarding anatomical successs. The anatomical successs rate in the standard silicone oil group was slightly higher (40%) compared to the HSO group (28%) in this study, however this was not statistically significant ( $p=0.27$ ). Duan et al<sup>20</sup> reported macular reattachment was achieved in 87.9% with first operation and 100% with second operation using HSO tamponade. The rate of retinal attachment after the HSO removal in Tognetto study was very high (92.3%) and only 7.7% of cases experienced a recurrence.

Intraocular tamponade that necessitate surgical removal included silicone oil, and heavy silicone oil (HSO). Silicone oil has a low specific gravity and thus "floats" in the eye, making it useful for retinal pathology in the superior fundus, whereas it does not provide good support to the inferior retina. For inferior tamponade, a 100% silicone oil fill is required.<sup>4</sup> Without a complete fill, not only will the tamponade effect be deficient, but the residual inferior aqueous compartment, which may also provide a bed in which migrating fibroblasts and growth factors can accumulate and potentially worsen PVR. Therefore most frequent complication with silicone oil internal tamponade is the persistence or the recurrence of inferior RD.<sup>18</sup> Heavy silicone oil, a new substance similar to silicone oil but with a higher specific gravity than that of water that called heavy silicone oil (a mixture of perfluorohexyloctane (F6H8) and silicone oil) would be useful in these particular cases complicated by recurrent inferior RD with PVR.<sup>18</sup>

PVR most frequently develops in the inferior retina or is at least most severe in the inferior retina. The predisposition for the inferior retina is believed to be a result of gravity, whereby the retinal pigment epithelial and inflammatory cells liberated into the vitreous cavity via retinal tears settle in the inferior vitreous.<sup>23</sup>

When Sulfur hexafluoride gas (SF6) used as tamponade, Brazitikos et al<sup>17</sup> reported 94% macular attachment. The anatomical success rate also high in Goto<sup>19</sup> study, 98% in the superior group and 80% in the inferior group ( $p < 0.05$ ). However this 2 studies only include primary PPV cases with PVR stage B or less. SF6 have shorter duration in the eye compare to C3F8, of about 10-14 days of gas in the eye. Meanwhile RRD with higher grade PVR need longer time of tamponade to gain attachment to the retina. The mean time required retina to attached in RD patients was about  $\pm 65\%$  in 2-3 weeks and  $\pm 90\%$  in 4-6 weeks.<sup>23</sup> In general gas should be used if intraocular tamponade for several weeks is deemed adequate to reattach the retina. Silicone oil is used when tamponade for more than 4 weeks is necessary.<sup>23</sup> The choice of a particular mixture of an intraocular gas is determined by the kinetics of disappearance of various compositions of intraocular gas. A long-acting tamponade using perfluoropropane is preferred in the majority of eyes with PVR.<sup>23</sup> In the Silicone Study, shorter-acting tamponade with sulfur hexafluoride was shown to have a lower success rate for PVR surgery and a higher complication rate.

Patients with complex or recurrent RD associated with PVR as focus of this review, reported by silicone study 1 and 2. Silicone study<sup>11,16</sup> reported that at most visits, attachment of the macula was significantly ( $p < 0.05$ ) more frequent in eyes randomized to silicone oil than in those randomized to SF6 gas (about 80% vs about 60%, respectively).<sup>11</sup> This increased reattachment, which persisted throughout the 2-year follow-up, is consistent with the rationale originally proposed for the use of silicone oil, namely, that closure of retinal breaks appeared more effective with silicone oil than with an SF6 gas bubble.<sup>11</sup> The anatomical success rate also higher in C3F8 than in SF6 group (73.9%

vs 57.5% respectively). The Silicone study 2 reported that the principal reason for the better results obtained with C3F8 gas than with SF6 gas was the longer duration of an effective intraocular tamponade with C3F8 gas than with SF6 gas.<sup>16</sup> As tamponade agents, C3F8 and silicone oil appear to have visual and anatomic advantages over SF6, especially within the first year after surgery, but SF6 may be a reasonable choice in certain clinical situations.<sup>24</sup> Isran<sup>8</sup> reported higher anatomical success (78.38%) than silicon study (73-80%) and several other study. This result may related to short followup time in this study that only 1 month.

There were no statistically significant differences between C3F8 gas and silicone oil in the likelihood of achieving macular attachment at the last follow-up examination (73.9% vs 73.8% respectively). Silicone oil has been considered advantageous in confining subretinal fluid outside the macular area even when partial posterior retinal redetachment occurs. Silicone study report 2 could not confirm any advantage of silicone oil over C3F8 gas in confining recurrent subretinal fluid to keep the macula attached in the presence of extramacular posterior retinal redetachment.<sup>16</sup> Anatomical success rates are stubbornly low with single operations: approximately 62–65%, despite a variety of methods used. Subtotal reattachment may be commoner. Patients who achieve a re-attached retina with the first operation have significantly better visual outcomes. Usually, the cause of failure is further PVR formation. Re-operations are usually required at 2 months, and such eyes require a mean of two operations.<sup>24</sup>

Silicone study 2<sup>16</sup> reported more than one surgery needed to achieve complete reattachment, about 21% eyes in both C3F8 and SO group. A total of 10% eyes were switched from C3F8 gas to silicone oil and only 2% of eyes were switched from silicone oil to C3F8 gas to achieve complete reattachment. The following subgroups showed better outcome with silicone oil: eyes with severe anterior PVR and those nonpreviously vitrectomized eyes that underwent relaxing retinotomy. The ideal tamponade agents must have several properties such as surface tension, expansile qualities,

and time of effective tamponade. Silicone oil is used in vitreoretinal surgery to provide long-term internal tamponade in cases of complicated retinal detachment. Even the C3F8 have the better surface tension than SO, SO have advantages that it does not lose volume in the postoperative period.<sup>22</sup> The use of SO as internal tamponade will change the vector of vertical traction from PVR become tangential within vitreous cavity.<sup>23</sup> SO have more advantages than C3F8 in several characteristic including: 1) provides extended tamponade for months or years, allowing surgeon to determine if and when to remove silicone oil; 2) the best tamponade for eyes with numerous retinal tears or large retinectomies; 3) better in achieving partial retinal reattachment in eyes with residual traction or reepithelialization.<sup>23</sup>

Currently available silicone oils come in 1000 centistoke and 5000 centistoke viscosities. Silicone oil is permanent and may eventually require surgical removal.<sup>15</sup> Silicone oil is widely used for long-term retinal tamponade. In patients who must engage in air travel or those who are unable to position, silicone oil may be used as an alternative to gas tamponade. Silicone oil must be removed from the eye at approximately 6 months or when complications develop before this.

## Complication

### • Recurrent RD

The most common late complication of PVR surgery is recurrent epiretinal proliferation leading to retinal detachment.<sup>23</sup> Jousseaume et al reported that redetachment occur in 44% eyes using silicone, and 50% eyes using HSO tamponade. Regarding the location of the redetachments under silicone oil, in the silicone group, redetachments were seen predominantly in the inferior quadrants between 3 over 6–9 o'clock. This is in contrast to the HSO group, where redetachments were more equally distributed to the upper and lower retina with a dominance of the upper quadrants.<sup>15</sup> Four eyes (12.1%) in Duan et al<sup>20</sup> series had recurrent RD because of PVR. They were all PVR D before operation, and three eyes had obvious choroidal detachment. This suggests that postoperative PVR is related to preoperative PVR, while HSO

tamponade cannot prevent the development of PVR. Silicone study 1 reported that recurrent retinal detachment developed immediately following oil removal in three (14%) of 21 eyes. This fact, along with rates of retinal detachment found by others (25%, 16%, and 33%), argues for not routinely removing silicone oil.<sup>11</sup> The reported rate of recurrence of RD in silicone oil-filled eyes ranges from 6% to >35% after silicone oil removal.<sup>18</sup>

### • Glaucoma

Glaucoma (greater than or equal to 21 mmHg) occurring in silicone oil-filled eyes has been extensively reported in the literature. Glaucoma can be an early postoperative complications but it may also occur as a late complication of PVR, especially in eyes with silicone oil tamponade.<sup>23</sup>

In Silicone study, both transiently and persistently elevated IOP was infrequent in eyes randomized to silicone oil and C3F8 (0.7% vs 1% respectively).<sup>16</sup> Elevated intraocular pressure is transient in most eyes and can be managed with topical or systemic aqueous suppressants.<sup>23</sup> Most eyes with elevated intraocular pressure have open angles with decreased aqueous outflow as a result of vitreous inflammation, blood, or the encircling scleral buckle. Rarely eyes may develop angle-closure glaucoma with a forward shift of the iris in aphakic eyes or lens-iris diaphragm in phakic or pseudophakic eyes. The intraocular gas bubble or silicone oil may contribute to a forward shift in the lens-iris diaphragm when the patient is upright or supine.<sup>23</sup>

The lack of elevated IOP in eyes randomized to silicone oil in Silicone study that were aphakic or underwent lensectomy in conjunction with vitrectomy confirms the effectiveness of an Inferior Pheripheral Iridectomy (IPI) in preventing pupillary block due to silicone oil in these circumstances. However, the development of chronic elevated IOP from silicone oil remains possible since this reportedly occurs some years after oil injection.<sup>11</sup> An inferior iridectomy is necessary in aphakic eyes filled with silicone oil to prevent or help avoid misdirection of aqueous. Overfilling of the vitreous cavity with silicone oil during surgery may also lead to angle closure, and this does not respond to



reformation of the anterior chamber. This is why it is important to verify that the anterior chamber is formed at a normal intraocular pressure when the surgery is completed and that the vitreous is filled with silicone oil.<sup>23</sup>

The incidence of glaucoma in silicone oil tamponade by Jousseaume et al<sup>15</sup> study was 23%. The incidence of glaucoma in HSO tamponade by Tognetto et al<sup>18</sup> study was 30.7%, this is similar to that reported for silicone oil use in vitreoretinal surgery by other authors. Isran reported only 5.4% of glaucoma, lower than other study. An increase in IOP is a common complication after PPV and silicone oil tamponade. A transient ocular hypertension has been recorded in between 12% and 70% of cases, and the development of glaucoma is recorded in up to 40% of cases.<sup>18</sup> In Tognetto study, the glaucoma due to overfilling of HSO. The elevated IOP resolved after partial aspiration of HSO. In 5 cases, IOP was controlled through topical therapy. Duan et al reported 18.2% patient had temporary rise in IOP (24-32 mmHg) postoperatively using HSO tamponade.

#### ● Cataract

Goto et al<sup>19</sup> reported 52% of the phakic eyes using SF6 tamponade, a cataract surgery was performed during the follow-up period because of increased lens opacification.

In silicone group, Jousseaume et al reported 4% cataract as complication, Isran reported 2.7% cataract. Cataract is the most common complication after HSO tamponade. Tognetto et al reported 19% of phakic patients developed cataract after HSO tamponade, meanwhile Duan et al reported 100% cataract occur after HSO tamponade.<sup>18,20</sup> The percentage of cataract incidence after silicone oil tamponade has been reported between 30% and 100%.<sup>18</sup> Factors that may contribute to lens opacification after HSO tamponade including: 1) HSO touches the lens directly, which may obstruct the normal metabolism of the lens; 2) An emulsified HSO droplet adhered to the hyaloid membrane behind the lens and formed an opacified membrane; 3) In complicated RD, the surgical procedure is comparatively longer, more debris of tissues and cells is formed during the operation, and

this might interfere with lens metabolism; 4) The viscosity of HSO is lower than that of conventional silicone oil, which allows HSO to move more freely in the vitreous cavity. This, along with the movement of an emulsified HSO droplet, may stimulate the posterior capsule and cause opacification of the posterior capsule and subcapsular cortex.<sup>20</sup>

#### ● Hypotony

The percentage of eyes with hypotony was higher in eyes randomized to SF6 (25% vs 10%) and C3F8 gas (30% vs 16%) than in those randomized to silicone oil.<sup>16</sup> The prevalence of hypotony was high and was strongly associated with the anatomical status of the retina.

In the Silicone Study, hypotony was less common in eyes treated with silicone oil than in those treated with C3F8. At the last follow-up examination, persistent hypotony was present in 30% of the eyes treated with C3F8 gas and in 16% of those treated with silicone oil in group 1 ( $P < 0.05$ ).<sup>16</sup> Using cross-sectional analysis hypotony did prove to be more prevalent in the group treated with C3F8 gas during the first 6 months of the study, it had virtually equalized between the two modalities by 18 months (about 20% for either modality).

Regardless of treatment, hypotony occurred with greater frequency in eyes with a detached macula than in those with macular attachment. The close association of hypotony and chronic retinal detachment is well recognized. In eyes in which the macula was attached, the prevalence of hypotony was small, irrespective of randomized modality.<sup>11</sup>

#### ● Keratopathy

Keratopathy is late complications of surgery for PVR. Keratopathy from corneal edema or opacification may contribute to decreased acuity in eyes with attached retinas between 6 months and 2 years after surgery.<sup>23</sup> Keratopathy developed in 27% of eyes treated successfully in the Silicone Study. The incidence of keratopathy was similar for eyes treated with intraocular gas or with silicone oil. Keratopathy is a well-recognized complication of silicone



oil, especially when the oil has remained in contact with the corneal endothelium. The use of an inferior iridectomy has been reported to reduce, but not eliminate, silicone keratopathy. Keratopathy associated with a gas tamponade has been created experimentally in animal eyes, but is much less recognized clinically.<sup>16</sup> Persistent keratopathy occurred in 48% eyes treated with SF6 gas and 21% eyes treated with silicone oil (P= 0.01).<sup>11</sup>

Silicone Study Report 2 showed that intraocular tamponade (either silicone or C3F8) had no influence on the incidence of keratopathy. Keratopathy and blindness were more frequent in eyes randomised to receive SF6.<sup>25</sup> The prevalence of keratopathy was twice as large in eyes treated with SF6 gas than in those treated with silicone oil.<sup>11</sup> The substantial prevalence of keratopathy with SF6 gas was unexpected. Although SF6 gas has been shown experimentally to damage corneal endothelial cells, this experimental finding was not previously thought to present a significant clinical problem.<sup>11</sup> C3F8 have higher incidence of keratopathy compare to silicone oil (33% vs 30%), however no significant differences in keratopathy between C3F8 gas and silicone oil.<sup>16</sup> Band keratopathy may develop in eyes treated with silicone oil, especially if the silicone oil touches the corneal endothelium. Removal of the silicone oil should be considered, if possible, in eyes with reattached retinas and band keratopathy.<sup>23</sup>

## CONCLUSION

As tamponade agents, C3F8 and silicone oil appear to have more visual and anatomic advantages over SF6 in participants with complex or recurrent RD associated with PVR, but SF6 may be a reasonable choice in RRD with low grade PVR and primary cases.

Silicone oil was better than C3F8 gas to obtain final visual and anatomic success in patient with recurrent RD associated with higher grade PVR, because it provides extended tamponade for months or years, can tamponade numerous retinal tears or large retinectomies, and better in achieving partial retinal reattachment in eyes with residual traction or re proliferation.

Heavy silicone oil would be useful in particular cases complicated by recurrent inferior RD with PVR.

Retinal redetachment, glaucoma, cataract, hypotony and keratopathy were reported in both gases and silicone group. The prevalence of cataract was highest in HSO group, related to low viscosity of HSO which allows HSO to move, stimulate the posterior capsule opacification. The prevalence of hypotony was highest in C3F8 group, related to chronic retinal detachment. The prevalence of keratopathy was highest in SF6 group, related to direct contact with the corneal endothelium and damage to corneal endothelial cells.

## REFERENCES

1. Lee E, ElHousseini Z, Steel DH, Williamson TH. An analysis of the outcomes for patients with failed primary vitrectomy for rhegmatogenous retinal detachment. *Graefes archive for clinical and experimental ophthalmology = Albrecht von Graefes Archiv fur klinische und experimentelle Ophthalmologie*. 2014.
2. Thompson JT. The absorption of mixtures of air and perfluoropropane after pars plana vitrectomy. *Archives of ophthalmology*. 1992;110(11):1594-7.
3. Kuhn F, Aylward B. Rhegmatogenous retinal detachment: a reappraisal of its pathophysiology and treatment. *Ophthalmic research*. 2014;51(1):15-31.
4. Young TA, D'Amico DJ. Controversies in proliferative vitreoretinopathy tamponade and pharmacologic adjuvants. *International ophthalmology clinics*. 2005;45(4):163-71.
5. Stern WH, Johnson RN, Irvine AR, Barricks ME, Boyden BS, Hilton GF, et al. Extended retinal tamponade in the treatment of retinal detachment with proliferative vitreoretinopathy. *The British journal of ophthalmology*. 1986;70(12):911-7.
6. Angunawela RI, Azarbadegan A, Aylward GW, Eames I. Intraocular fluid dynamics and retinal shear stress after vitrectomy and gas tamponade. *Investigative ophthalmology & visual science*. 2011;52(10):7046-51.
7. Heimann H, Bartz-Schmidt KU, Bornfeld N, Weiss C, Hilgers RD, Foerster MH. Scleral buckling versus primary vitrectomy in rhegmatogenous retinal detachment: a prospective randomized multicenter clinical study. *Ophthalmology*. 2007;114(12):2142-54.
8. Isran, Mallebi AAV. Vitrektomi dan tamponade silikon pada ablasio retina dengan vitreoretinopati proliferatif. *Ophthalmologica Indosiana*. 2007;34(1):83-90.
9. Rojas J, Fernandez I, Pastor JC, MacLaren RE, Ramkissoon Y, Harsum S, et al. Predicting proliferative vitreoretinopathy: temporal and external validation of models based on genetic and clinical variables. *The British journal of ophthalmology*. 2014.
10. Schwartz SG, Flynn HW, Jr., Lee WH, Wang X. Tamponade in surgery for retinal detachment associated with proliferative vitreoretinopathy. *The Cochrane database of systematic reviews*. 2014;2:CD006126.

11. Vitrectomy with silicone oil or sulfur hexafluoride gas in eyes with severe proliferative vitreoretinopathy: results of a randomized clinical trial. Silicone Study Report 1. *Archives of ophthalmology*. 1992;110(6):770-9.
12. Howick J, Chalmers I, Glasziou P, Greenhalgh T, Heneghan C, Liberati A, et al. *The Oxford 2011 Levels of Evidence*. Oxford 2011.
13. The classification of retinal detachment with proliferative vitreoretinopathy. *Ophthalmology*. 1983;90(2):121-5.
14. Machemer R, Aaberg TM, Freeman HM, Irvine AR, Lean JS, Michels RM. An updated classification of retinal detachment with proliferative vitreoretinopathy. *American journal of ophthalmology*. 1991;112(2):159-65.
15. Jousseaume AM, Rizzo S, Kirchhof B, Schrage N, Li X, Lente C, et al. Heavy silicone oil versus standard silicone oil in as vitreous tamponade in inferior PVR (HSO Study): interim analysis. *Acta ophthalmologica*. 2011;89(6):e483-9.
16. Vitrectomy with silicone oil or perfluoropropane gas in eyes with severe proliferative vitreoretinopathy: results of a randomized clinical trial. Silicone Study Report 2. *Archives of ophthalmology*. 1992;110(6):780-92.
17. Brazitikos PD, Androudi S, Christen WG, Stangos NT. Primary pars plana vitrectomy versus scleral buckle surgery for the treatment of pseudophakic retinal detachment: a randomized clinical trial. *Retina*. 2005;25(8):957-64.
18. Tognetto D, Minutola D, Sanguinetti G, Ravalico G. Anatomical and functional outcomes after heavy silicone oil tamponade in vitreoretinal surgery for complicated retinal detachment: a pilot study. *Ophthalmology*. 2005;112(9):1574.
19. Goto T, Nakagomi T, Iijima H. A comparison of the anatomic successes of primary vitrectomy for rhegmatogenous retinal detachment with superior and inferior breaks. *Acta ophthalmologica*. 2013;91(6):552-6.
20. Duan A, She H, Qi Y. Complications after heavy silicone oil tamponade in complicated retinal detachment. *Retina*. 2011;31(3):547-52.
21. Tan HS, Oberstein SY, Mura M, Bijl HM. Air versus gas tamponade in retinal detachment surgery. *The British journal of ophthalmology*. 2013;97(1):80-2.
22. Brinton DA, Wilkinson CP. Pneumatic Retinopexy. In: Richard K. Parrish I, editor. *Retinal Detachment: Principles and Practice*, Third Edition New York: Oxford University Press; 2009. p. 181-93.
23. Thompson J. Proliferative vitreoretinopathy. In: Ryan SJ, editor. *retina*. 4 ed. St louis: Elsevier-Mosby Inc; 2006. p. 2283-310.
24. Williamson TH. Proliferative Vitreoretinopathy. In: Philipp M, editor. *Vitreoretinal Surgery*. New York: Springer-Verlag Berlin Heidelberg; 2008. p. 119-25.
25. Alexander P, Prasad R, Ang A, Poulson AV, Scott JD, Snead MP. Prevention and control of proliferative vitreoretinopathy: primary retinal detachment surgery using silicone oil as a planned two-stage procedure in high-risk cases. *Eye (Lond)*. 2008;22(6):815-8.
26. Ross WH, Stockl FA. Visual recovery after retinal detachment. *Current opinion in ophthalmology*. 2000;11(3):191-4.