

## CASE REPORT

# Pneumatic Retinopexy in Rhegmatogenous Retinal Detachment : Case Series

**Fauzan Teuku Banta<sup>1</sup>, Ari Djatikusumo<sup>2</sup>, Elvioza<sup>2</sup>, Gitalisa Andayani<sup>2</sup>, Anggun Rama Yudhanta<sup>2</sup>, Mario Marbungaran Hutapea<sup>2</sup>, Andi Arus Victor<sup>2</sup>**

<sup>1</sup>RSUD dr. Fauziah, Bireun, Aceh, Indonesia

<sup>2</sup>Department of Ophthalmology, Faculty of Medicine, University of Indonesia

*E-mail: arvimadao@yahoo.com*

## ABSTRACT

In the case of rhegmatogenous retinal detachment (RRD), pneumatic retinopexy is an alternative choice besides scleral buckling and pars plana vitrectomy. This case series describes two cases of RRD with superotemporal tear treated successfully with pneumatic retinopexy. The expandable gas used in this study was 0.4 cc perfluoropropane (C<sub>3</sub>F<sub>8</sub>) gas, patient's head is immediately positioned face down (prone), then slowly turned into an upright position in accordance with the tear for 1-3 days. Laser retinopexy using an argon laser is performed after the retina is properly reattached. Ten months after pneumatic retinopexy, the VA of RE in case I remained at 6/18 with reattached retina. At four weeks, VA of RE in case II was at 3/60 with reattached retina. VA of both cases was relatively satisfactory with retinal reattachment in a single procedure. The anatomical and functional success of pneumatic retinopexy is related to macular status before surgery, retinal detachment area, phakic status, or the presence of PVR and high myopia.

**Keywords :** Rhegmatogenous, retinal detachment, pneumatic retinopexy

Retinal detachment is the separation of the neurosensory retinal layer from the retinal layer of the pigment epithelium with accumulation of sub-retinal fluid. There are three types of retinal detachments, namely rhegmatogenous, exudative, and tractional. Rhegmatogenous retinal detachment (RRD) is the most common type.<sup>1-3</sup>

The purpose of surgery on RRD is to close the retinal tear and release vitreous traction from the retina in the hope of obtaining an anatomical success in the form of permanent retinal attachment and restoration of visual function. The operating technique currently used in the management of retinal detachment is based on the evolution of various techniques that have

been studied. The technique is mainly divided into pneumatic retinopexy, scleral buckle, pars plana vitrectomy with intra-ocular tamponade.<sup>4-8</sup>

Pneumatic retinopexy is a minimally invasive and non-incisional procedure for RRD therapy. Pneumatic retinopexy is done by injecting transconjunctival gas through pars plana. This procedure was first introduced by Rosengren in 1938, but at that time this method was not widely practiced until it was published by Hilton and Grizzard in 1986, and currently known as modern pneumatic retinopexy.<sup>4,9,10</sup> Closure of retinal tears using tamponade gas bubbles will occur due to the influence of gas-liquid surface pressure and "flotation effect" on

retinal tears. Then laser photocoagulation or cryocoagulation is performed for a more permanent retinal attachment. The gas that is usually used in this technique is 0.3-0.6 ml 100% sulfur hexafluoride (SF<sub>6</sub>) or 0.3 ml of 100% C<sub>3</sub>F<sub>8</sub>. The purpose of the injection of expandable gas into the vitreous cavity is to keep the retina in position, and permanent retinal tears can be bonded with laser photocoagulation or cryocoagulation. Front-eye para-syntheses are often needed to reduce intraocular pressure as a result of the gas injection.<sup>11,12,13,14</sup> The major complication for pneumatic retinopexy is the formation of new retinal tears, which usually occurs at the inferior area. The injected gas can move into the sub-retina layer, especially if the gas bubble is in the form of "fish eggs". The lens and retina can be accidentally punctured by a needle. The risk of endophthalmitis is the risk of infection that can occur as well as the risk of all intraocular interventions.<sup>7,15,16</sup>

This procedure has several advantages such as higher patient comfort, cheaper cost, relatively simpler, requires minimal manipulation, and less postoperative refraction changes. The incidence of cataract formation after pneumatic retinopexy is also reported to be much lower than other techniques.<sup>2, 3</sup>

In addition, pneumatic retinopexy can be performed in an office setting, hence reducing operating room delays. Collaboration with patients is an important factor to maintain the effect of intraocular tamponade from gas to achieve the desired results. A better results of visual acuity are often reported in this procedure.

The procedure for pneumatic retinopexy used in this study was as follows: (1) The patient was laid down on the operating table; (2) Aseptic and antiseptic steps were performed; (3) Installation of eye drapes and blepharostat were installed; (4) Paracentesis of 0.2 cc of vitreous; (5) Intraocular injection of 0.4 cc perfluoropropane (C<sub>3</sub>F<sub>8</sub>) gas with 30G needle right in front of the plane gently and quickly to form a single gas bubble and to avoid the formation of fish egg gas bubbles

or small bubbles that will reduce visualization and tamponade effectiveness.<sup>9,17,18</sup> After the gas was injected, patient's head is immediately positioned face down (prone), then slowly turned into an upright position in accordance with the tear for 1-3 days. The patient position after the gas injection is paramount; the patient will undergo funduscopy examination within 1-3 days after gas injection. Laser retinopexy using an argon laser is performed after the retina is properly reattached. The position of the gas bubble can be shifted so that the laser retinopexy can be performed in an easier manner.<sup>11,17,19</sup>

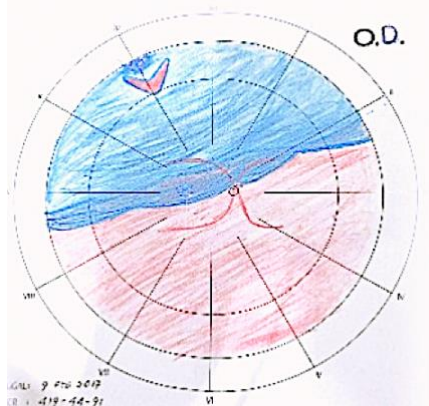
The purpose of this case series is to describe two cases of RRD with a break or tear located in the superotemporal treated successfully with pneumatic retinopexy.

## CASE SERIES

### Case 1

A 48 year-old woman, works as a domestic worker, was referred from Permata Bekasi Hospital on 9 February 2017 with a chief complaint of dark spot at the bottom of her right eye vision since 10 days ago. There is no history of using high powered myopic glasses, no history of trauma, and no history of eye surgery. Past medical history of systemic diseases is unremarkable. The general health status is within normal limits. From ophthalmic exam, the visual acuity (VA) of right eye (RE) = 0.5/60 (correction +2) = 3/60 and no improvement with pinhole (PH), VA of left eye (LE) = 0.5/60 and no improvement with PH. Intraocular pressure (IOP) of RE = 11.3 mmHg and IOP of LE = 14.0 mmHg, anterior segment is within normal, posterior segment examination found a retinal detachment at two superior quadrants of the RE, with a superotemporal horseshoe-shaped tear at the 11 o'clock meridian within one clock hour and negative macular reflex. The patient was diagnosed with RRD of the RE and immediately scheduled for pneumatic retinopexy with topical anesthesia.

The postoperative therapy is Cendo P-pred (contains neomycin sulphate, prednisolone acetate, and polymyxin B sulphate ) 6 drops daily, Cendo LFX (Levofloxacin 5 mg/ml) 6 drops daily, Ciprofloxacin 500 mg twice daily and mefenamic acid 500mg 2x1 tablets per day. Postoperative position instructions are half an hour of head-down prone position, 15 minutes of head-up prone, and then continued with semi fowler position with the left cheek pressed against the pillow. On the first follow-up day, VA of RE was 6/45 and no improvement with PH. Examination of the posterior segment found reattached retina and gas-filled vitreous cavity. IOP was within normal. Cendo P-Pred 6 drops daily and Cendo LFX 6 drops daily therapies were continued. On the second follow-up day, one week after the gas injection, VA of RE improved to 6/30 but no improvement with PH. Posterior segment examination revealed reattached retina and gas-filled vitreous cavity. Hence, laser retinopexy was performed with a total number of burns of 935, 240 mW power, 0.1 seconds time setting, and spot size of 200  $\mu$ m. Three months after the injection, there was a VA improvement of the RE to 6/24. At four months follow-up, VA of RE improved to 6/18. The patient was then advised to return for follow-up after 6 months. Ten months after pneumatic retinopexy, the VA of RE remained at 6/18 with reattached retina.



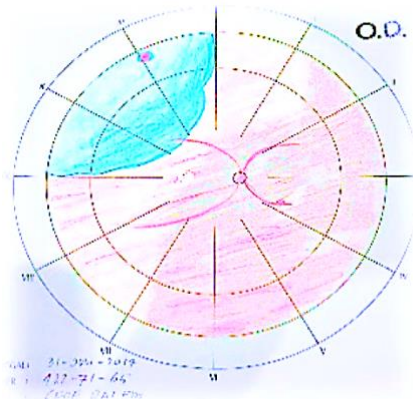
**Fig 1.** Funduscopy illustration of case I showing a retinal detachment at two superior quadrant of the RE, with a superotemporal horseshoe-shaped tear at the 11 o'clock meridian within one clock hour

## Case 2

A 62-year-old man was referred from the Tangerang Regional Public Hospital on 31 July 2017 with the chief complaint of blurred RE since 1 month ago. There was no history of high-powered myopic glasses, trauma, or eye surgery. Past medical history and systemic abnormalities were unremarkable. The general health condition was within normal limits. From ophthalmic examination, VA of RE = 3/60 (correction S + 2.50) = 6/45 and no improvement with PH, VA of LE = 6/12 (correction S-0.75) = 6/6. IOP of RE = 10.3 mmHg and IOP of LE = 12.0 mmHg. Examination of the anterior segment revealed grade II turbidity of the lens.

From posterior segment examination, retinal detachment was found at the superior temporal quadrant of the RE and a superotemporal break at 11 o'clock meridian within 1 clock hour with a positive macular reflex. The patient was diagnosed with RRD of RE without proliferative vitreoretinopathy (PVR) and immature senile cataracts on both eyes. Expandable gas injection was performed after the diagnosis was made and on the first day of follow-up, postoperative posterior segment examination showed reattached retina and the gas-filled vitreous cavity. IOP of both eyes was within normal. Pharmacological therapies given were Cendo P-Pred 6 drops daily and cendo LFX 6 drops daily. Patients were advised to return for follow-up in one week.

On second follow-up day, one week after gas injection, VA of RE was at 3/60. Examination of the posterior segment showed reattached retina and gas-filled vitreous cavity. Laser retinopexy was performed with a total number of burns of 454, 240 mW power, 0.1-0.2 seconds time setting, and spot size of 200  $\mu$ m. Three weeks after gas injection, the uncorrected VA of RE was 6/60, the IOP was 14 mmHg, and retina was reattached.



**Fig 2.** Funduscopy illustration of case 2 showing retinal detachment at the superior temporal quadrant of the RE and a superotemporal break at 11 o'clock meridian within 1 clock hour

All patients in this case series were operated in the operating theater. The laser photocoagulation was performed within one week after the gas injection procedure. Cataract complications were not found in both cases. The informed consent form about the postoperative head position was fully explained to the patient.

## DISCUSSION

In RRD, pneumatic retinopexy carried out by Ryan SJ at symptom length  $\leq 7$  days, with the retinal detachment area limited to 1-2 quadrants, the location of the retinal tear at superotemporal, macular on and maximal grade B PVR and the phakic eye. Pneumatic retinopexy requires accurate peripheral retinal examination. Therefore, if the vitreous base is blocked by the presence of cortex, posterior capsule and vitreous opacities or lens opacities, then this pneumatic retinopexy action should be avoided.<sup>19-21</sup> According to Ryan, an indication of pneumatic retinopexy is that the location of retinal tears is greater than 1 hour or multiple tears that extend for more than 1 hour, inferior tear of the retina by 4 hours, the presence of grade C or D PVR, people with glaucoma, pseudophakic anterior IOL, physical or mental disability which makes it difficult to maintain the necessary position, and media opacity which makes it difficult to examine the

retina. Some experts had tried to take treat inferior retinal tear, but with a very uncomfortable post-operation position for the patient, i.e. the downward-tilted head-down position to achieve the effects of tamponade on the retinal tears. Ten out of thirteen (76.9%) eyes with inferior detachment achieved reattachment with pneumatic retinopexy in a study by Hwang (2011)<sup>22</sup>, and a study by Sharma (2004) achieved successful reattachment with a single operation in 39 out of the 48 patients (81.3%) with inferior breaks<sup>23</sup>. Another study by Chang (2003) also supported the high rate of success using inverted pneumatic retinopexy for inferior retinal break with 10 out 11 reattachment rate.<sup>24</sup> Patient cooperation is crucial for the desired the gas bubble tamponade effects of pneumatic retinopexy.<sup>19, 20, 25</sup>

In this case series, all patients were injected with 100% C<sub>3</sub>F<sub>8</sub> to provide a more optimal tamponade effect. Macular hole closure rates have been reported in studies comparing water (20%) versus SF<sub>6</sub> (20%), and C<sub>3</sub>F<sub>8</sub> (12-16%).<sup>26</sup> The primary reattachment rate was 78.13%, final reattachment rate was 96.88%, air tamponade had equivalent effects with C<sub>3</sub>F<sub>8</sub> gas tamponade in the management of RRDs with inferior breaks.<sup>27</sup> Short-term anatomical and visual outcomes were similar in eyes treated with either SF<sub>6</sub> or C<sub>3</sub>F<sub>8</sub>, independently to the stage of the macular hole.<sup>28</sup>

About 40% of all RRD can be repaired using a pneumatic retinopexy procedure. The reason for the underutilization of pneumatic retinopexy is that inability to eliminate the vitreoretina traction, difficulty to explore all possible retinal break, and high variability in patient compliance for postoperative positioning.<sup>6,29</sup> The success rate of pneumatic retinopexy surgery has been reported by Chan et al (2008).<sup>14</sup> In the report, it was stated that the success rate of a single procedure pneumatic retinopexy in phakic patients was between 71-84%. In pseudophakic patients, the success rate is lower at 41-67%. A multicenter randomized

controlled trial comparing pneumatic retinopexy and scleral buckling revealed that postoperative vision of 20/50 or better at 6 months follow-up showed better results in pneumatic retinopexy, i.e. 80% compared to 56% in scleral buckling procedure. Vision rehabilitation was also significantly faster in the pneumatic retinopexy group. In the PIVOT test, patients who underwent pneumatic retinopexy also had better VA results than vitrectomy in the first one year.<sup>4,30,31</sup>

The incidence of new tears after the pneumatic retinopexy procedure has been reported at 22% and mostly occurs in the inferior area in the countercoupe position.<sup>4,29,31</sup>

VA of both cases was relatively satisfactory with retina reattached in a single operation. This is due to the phakic status, still-attached macula, retinal detachment area is still limited to 1 or 2 quadrants, and absence of PVR. This is in accordance with another study which states that the postoperative VA is affected by macular status before surgery, duration of detached macula, history of difficult surgery, or the presence of PVR. Detachment of the macula can cause photoreceptor degeneration that hampers postoperative VA improvement. According to several studies, the success rate of pneumatic retinopexy in the pseudophakic eye is lower than in the phakic eye.<sup>5,18,31</sup>

## CONCLUSION

Anatomical and functional success of pneumatic retinopexy is related to macular status before surgery, retinal detachment area, phakic status, or the presence of PVR.

## ACKNOWLEDGEMENTS

This study received no specific grant from any funding agency or institution.

## References

1. Assi AC, Chateris DG, Gregor ZJ. Practice patterns of pneumatic retinopexy in the United Kingdom. *The British journal of ophthalmology*. 2001;85(2):244.
2. Hwang JC. Regional practice patterns for retinal detachment repair in the United States. *American journal of ophthalmology*. 2012;153(6):1125-8.
3. Schaal S, Sherman MP, Barr CC, Kaplan HJ. Primary retinal detachment repair: comparison of 1-year outcomes of four surgical techniques. *Retina (Philadelphia, Pa)*. 2011;31(8):1500-4.
4. Kim RY, D'Amico DJ. Postoperative Complications of Pneumatic Retinopexy. *International Ophthalmology Clinics*. 2000;40(1):165-73.
5. Feng H, Adelman RA. Cataract formation following vitreoretinal procedures. *Clinical ophthalmology (Auckland, NZ)*. 2014;8:1957-65.
6. Taher RM, Haimovici R. Anterior chamber gas entrapment after phakic pneumatic retinopexy. *Retina (Philadelphia, Pa)*. 2001;21(6):681-2.
7. Tan C, Wee K, Zaw MD, Lim TH. Anterior chamber gas bubble following pneumatic retinopexy in a young, phakic patient. *Clinical & experimental ophthalmology*. 2011;39(3):276-7.
8. Sharma T. Post-Pneumatic Retinopexy Endophthalmitis: Management of Infection and Persistent Retinal Detachment. *Ophthalmic surgery, lasers & imaging : the official journal of the International Society for Imaging in the Eye*. 2010:1-2.
9. Muni RH. Randomized trial comparing pneumatic retinopexy vs. vitrectomy in the management of primary rhegmatogenous retinal detachment (PIVOT): 1-year results. *American Society of Retina Specialists 35th Annual Meeting*; 11-15 August 2017; Boston, MA, USA.
10. Sinkar SN, Simon SJ, Gilhotra JS. Giant retinal tear after pneumatic retinopexy. *Retinal cases & brief reports*. 2012;6(2):151-2.
11. Abecia E, Pinilla I, Oliván JM, Larrosa JM, Polo V, Honrubia FM. Anatomic results and complications in a long-term follow-up of pneumatic retinopexy cases. *Retina (Philadelphia, Pa)*. 2000;20(2):156-61.
12. Friberg TR, Eller AW. Laser pneumatic retinopexy for repair of recurrent retinal detachment after failed scleral buckle--ten years experience. *Ophthalmic surgery and lasers*. 2001;32(1):13-8.
13. Goldman DR, Shah CP, Heier JS. Expanded criteria for pneumatic retinopexy and potential cost savings. *Ophthalmology*. 2014;121(1):318-26.
14. Chan CK, Lin SG, Nuthi AS, Salib DM. Pneumatic retinopexy for the repair of retinal

- detachments: a comprehensive review (1986-2007). *Survey of ophthalmology*. 2008;53(5):443-78.
15. Mansour AM. Pneumatic retinopexy for inferior retinal breaks. *Ophthalmology*. 2005;112(10):1771-6.
  16. Mudvari SS, Ravage ZB, Rezaei KA. Retinal detachment after primary pneumatic retinopexy. *Retina (Philadelphia, Pa)*. 2009;29(10):1474-8.
  17. Modi YS, Townsend J, Epstein AE, Smiddy WE, Flynn HW, Jr. Pneumatic retinopexy for retinal detachment occurring after prior scleral buckle or pars plana vitrectomy. *Ophthalmic surgery, lasers & imaging retina*. 2014;45(5):409-13.
  18. Petrushkin HJ, Elgohary MA, Sullivan PM. Rescue Pneumatic Retinopexy in Patients with Failed Primary Retinal Detachment Surgery.. *Retina (Philadelphia, Pa)*. 2015;35(9):1851-9.
  19. Yam JC, Liu DT, Lee VY, Lam PT, Lam DS. Giant retinal tear after pneumatic retinopexy. *Acta ophthalmologica*. 2008;86(2):232-3.
  20. Ryan SJ. *Retina. Surgical Retina*. Philadelphia: JB Lippincott Company; 2018. p. 1943-56
  21. Sugiarti ED. Karakteristik penderita dan gambaran hasil operasi ablasio retina regmatogen di Rumah Sakit Mata Cicendo Periode Januari-Desember 2007. [Observational study ]. In press 2009.
  22. Hwang JF, Chen SN, Lin CJ. Treatment of inferior rhegmatogenous retinal detachment by pneumatic retinopexy technique. *Retina (Philadelphia, Pa)*. 2011;31(2):257-61.
  23. Sharma A, Grigoropoulos V, Williamson TH. Management of primary rhegmatogenous retinal detachment with inferior breaks. *The British journal of ophthalmology*. 2004;88(11):1372-5.
  24. Chang TS, Pelzek CD, Nguyen RL, Purohit SS, Scott GR, Hay D. Inverted pneumatic retinopexy: a method of treating retinal detachments associated with inferior retinal breaks. *Ophthalmology*. 2003;110(3):589-94.
  25. Jun AS, Pieramici DJ, Bridges WZ, Jr. Clear corneal cataract wound dehiscence during pneumatic retinopexy. *Archives of Ophthalmology*. 2000;118(6):847-8.
  26. Kim SS, Smiddy WE, Feuer WJ, Shi W. Outcomes of sulfur hexafluoride (SF6) versus perfluoropropane (C3F8) gas tamponade for macular hole surgery. *Retina (Philadelphia, Pa)*. 2008;28(10):1408-15.
  27. Zhou C, Qiu Q, Zheng Z. Air versus Gas Tamponade in Rhegmatogenous Retinal Detachment with Inferior Breaks After 23-Gauge Pars Plana Vitrectomy : A Prospective, Randomized Comparative Interventional Study. *Retina (Philadelphia, Pa)*. 2015;35(5):886-91.
  28. Casini G, Loiudice P, De Cilla S, Radice P, Nardi M. Sulfur hexafluoride (SF6) versus perfluoropropane (C3F8) tamponade and short term face-down position for macular hole repair: a randomized prospective study. *International journal of retina and vitreous*. 2016;2:10.
  29. Moshfeghi AA, Salam GA, Deramo VA, Shakin EP, Ferrone PJ, Shakin JL, et al. Management of macular holes that develop after retinal detachment repair. *American journal of ophthalmology*. 2003;136(5):895-9.
  30. Yee KMP, Sebag J. Long-term results of office-based pneumatic retinopexy using pure air. *British Journal of Ophthalmology*. 2011;95(12):1728-30.
  31. Lee HN, Lin KH, Tsai HY, Shen YC, Wang CY, Wu R. Aniseikonia following pneumatic retinopexy for rhegmatogenous retinal detachment. *American journal of ophthalmology*. 2014;158(5):1056-61.