
CASE REPORT

Intraorbital Wooden Foreign Body with Intracranial Extension : A Case Report

Amanda N Shinta P, Purjanto T Utomo, Agus Supartoto

Department of Ophthalmology, Faculty of Medicine

Gadjah Mada University, Yogyakarta

E-mail: amanda_n_shinta@yahoo.com

ABSTRACT

Purpose : The aim of this study is to report a case of intraorbital wooden foreign body with intracranial extension to the frontal lobe and its management.

Method : This is a descriptive study: A 53 year-old male referred due to wooden stick stucked in the orbital cavity causing protruding eyeball and vital sign instability.

Result : Right eye examination revealed light perception visual acuity, with bad light projection and bad color perception, inwardly folded upper eyelid, proptosis, conjunctival chemosis, corneal erosion and edema, dilated pupil with sluggish pupillary light reflex and limited ocular movement in all direction. Vital sign was unstable with decreasing blood pressure, increasing temperature and heart rate. CT Scan showed complete fracture of the orbital roof due to penetration of the wooden stick, pneumoencephalus, cerebral edema and hematoma. Emergency craniotomy was performed to remove the penetrating wooden stick and bone segment in the frontal lobe and fracture repair. Ophthalmologist pulled the remaining stick, released the superior rectus muscle and repaired the lacerated eyelid. Outcome visual acuity was no light perception with lagophthalmos and limited ocular motility. Patient was admitted to Intensive Care Unit one day post-operatively and treated with systemic and topical antibiotic.

Conclusion : Any case presenting with intraorbital foreign body must undergo immediate neuroimaging to exclude any intracranial extension, especially in patients with worsening general condition.

Keywords: intraorbital foreign body, wooden foreign body, orbital roof fracture

Eye injuries are often associated with orbital foreign bodies, which are metallic (magnetic, non-magnetic) and non-metallic (plants, plastics, glass, etc). Wooden foreign bodies due to the pore on their surface and the

characteristics of organic matter, are a great bacterial growth medium, and if not promptly removed, they may lead to infection. In addition, the wooden foreign bodies are fragile and difficult to remove completely; thus the procedure is much

more difficult compared with metal foreign bodies. Diagnosis and treatment of wooden foreign bodies are rarely reported.

There have been reports of unusual foreign objects that have entered the intracranial cavity through the orbit. The term used is transorbital penetrating injury (TPI), which is a rare form of severe head injury. Two classes of projectiles are implicated in TPI, missile and non-missile, which are defined based on their velocity on impact. Non-missile projectiles have an impact velocity of less than 100 m/s, and injury is usually caused by tissue laceration and maceration, while missile projectiles cause injury via kinetic and thermal energies. Major neurological deficits may not manifest immediately and may be underestimated. If the foreign body is retained in the orbit or cranial cavity, severe infectious complications may occur later.

Hereby we reported a case about an intraorbital wooden foreign bodies with intracranial extension. Inform consent was signed by the patient and he agreed his condition being reported and published in an academic forum.

CASE ILLUSTRATION

A 53-year old man presented to our emergency department after he cut a wooden log with an electric rotating saw and a wooden stick penetrated his head through his right eye. He complained of pain in his right eye with significant decreased of vision. He was conscious (Glasgow Coma Scale 15/15), and his vital parameter was of 110/60 mmHg for blood pressure, 20x/min respiration rate and 88x/min heart rate and afebrile at the point of presentation. Physical examination revealed a protruding eyeball with wooden stick protruding out through the medial portion of his right eye (Fig.1).

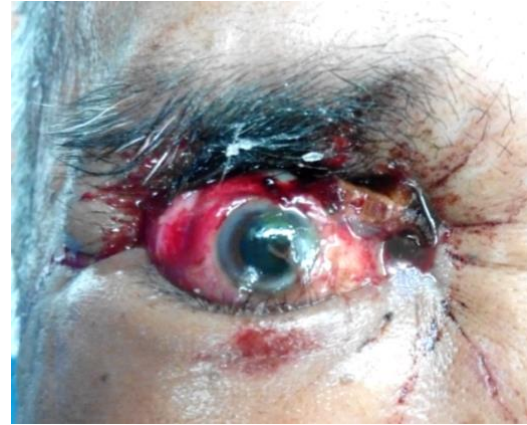

Fig 1. Protruded globe and inwardly folded upper eyelid

The eyeball was protruding with an inwardly folded upper eyelid. Other physical findings were light perception visual acuity with bad light projection and bad color perception, conjunctival chemosis, corneal erosion, and deep anterior chamber with mild to moderate inflammatory reaction, round pupil with a diameter of 6 mm with sluggish pupillary light reflex. Intraocular pressure was low at palpation with limited ocular motility to all direction.

During physical examination and history taking, his general condition worsened. He experienced a decreased level of consciousness (Glasgow Coma Scale 13/15 – E3V5M5). His heart rate increased to 100x/minute, blood pressure decreased to 97/45 mmHg and temperature rose to 38,5°C. An immediate CT scan of the head was performed and revealed that the wooden stick entered the cranium through the orbital roof causing orbital roof fracture (Fig.2). Other findings found on CT scan were complete fracture of the orbital roof due to penetration of the wooden stick, pneumoencephalus, cerebral edema and hematoma. The surgical procedure was carefully planned after reviewing the radiological images in different projections.

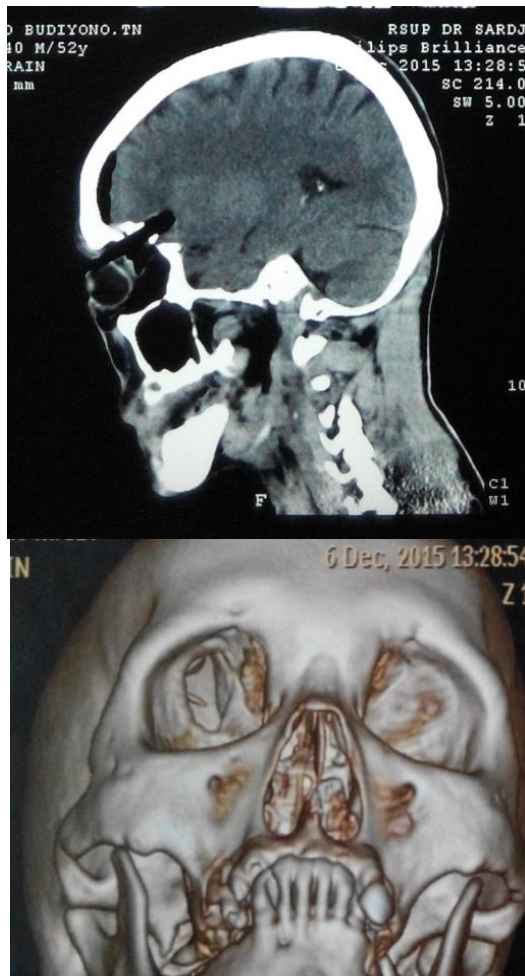


Fig 2. Head CT scan revealed fracture of the orbital roof and intracranial extension of the foreign body to the right frontal lobe

Surgery was performed by an ophthalmologist and a neurosurgeon. The neurosurgeon performed a craniotomy with bicoronal incision. After the cranium was

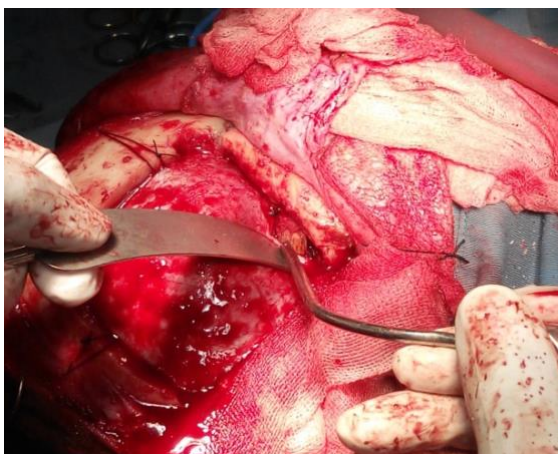


Fig 3. The wooden foreign body penetrated the right frontal lobe

elevated, cerebral edema and an epidural hemorrhage found at frontobasal aspect. The area was explored and there was found a wooden stick penetrating the orbital roof (fragment I), duramater and frontal lobe (Fig.3).

The brain-penetrating wooden stick was pulled by the ophthalmologist from outside and the neurosurgeon was in charge for the hemostatic control of the intracranial hemorrhage, followed by repair of the orbital roof fracture, lacerated duramater and debridement. Upper eyelid was folded inwardly with protruding eyeball.

Exploration of the orbital cavity revealed another wooden foreign body without intracranial extension (fragment II) (Fig.4). The ophthalmologist evacuated the wooden foreign body by pulling it out of the orbital cavity, and superior rectus muscle appeared avulsed. After all wooden foreign bodies were evacuated, superior eyelid could be repositioned to its anatomical position and appeared the eyelid was lacerated in a size of 2 x 3.5 cm. The laceration was then sutured with prolene 6.0. Patient was given broad-spectrum antibiotics.

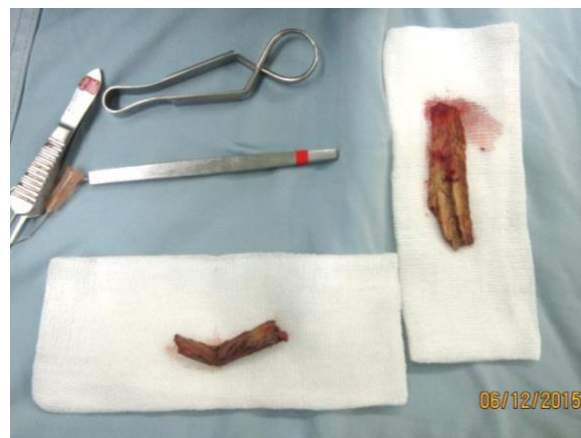

Fig 4. Two wooden sticks extracted from orbital cavity

She had an uneventful postoperative course and was discharged on the 8th postoperative day. At 2 weeks follow-up, patient was conscious and oriented. His Glasgow Coma Scale score was 15/15. No memory, speech and personality

impairment observed. He was afebrile and good general condition. No evidence of infection. The right eye was lagophthalmic, with The left eye, the non-injured eye was perfectly fine with no impairment.

DISCUSSION

Orbital foreign bodies are often found in bounce injury or puncture injury while people are working or playing. The foreign bodies are usually tree branches, chopsticks, corn stalks, bamboos and wood.

The case presented here is about a man who did a woodworking and had a wooden stick bounced and penetrated inside his eye. This man's first presentation was within normal vital sign. The wooden foreign body was quite small in size and thought to be just penetrated the orbital cavity. As time went by, his general condition worsened, his heart rate increased into 100x/minute, blood pressure decreased into 97/45 mmHg and temperature rose to 38,5°C. There we suspected that the wooden foreign body was just not inside the orbital cavity. We performed immediate head CT Scan and it revealed that the foreign body penetrated the cranial cavity, so it is called transorbital penetrating injury (TPI). The worsening general condition might be due to sepsis caused by the wooden foreign body. The surface of wooden foreign bodies is rough, as well as bacteria and parasites can easily attach to them. If foreign bodies penetrate into the orbit or remain and are not removed timely, acute inflammatory reaction will occur. Wooden foreign bodies will be calcified and organized, and inflammatory granuloma can grow in the surrounding. Hence, we performed an immediate foreign body removal by open craniotomy in the emergency operating room. Wooden foreign body in orbit is fragile. In order to avoid wooden foreign bodies remained, surgeons should completely remove them,

and use antibiotics to repeatedly rinse orbit cavity when removing the foreign bodies.

Organic foreign bodies are well-known causes of infection, regardless of the anatomical site. In the presence of an intracranial penetration, the management of the infection will be more complicated, and antibiotics which have good blood-brain barrier penetration, are recommended. If there is a suspicion of intracranial penetration, the empiric antibiotic therapy should include a third-generation cephalosporin and vancomycin. The previous studies have shown no predominant organism. However, cocci, rods, and anaerobes were predominant (*S. epidermidis*, *S. aureus*, *E. agglomerans*, *C. perfringens*). Fungal organisms do not play a significant role in intraorbital wooden foreign body. This patient received a broad spectrum antibiotic which covered both gram negative and positive bacteria and also anaerobe. No signs of infection observed and patient's general condition got better postoperatively.

CONCLUSION

Any case presenting with intraorbital foreign body must undergo immediate neuroimaging to exclude any intracranial extension, especially in patients with worsening general condition. Sepsis is the most dangerous life threatening course from this kind of eye trauma and immediate evacuation is mandatory.

REFERENCES

1. American Academy of Ophthalmology, 2014, Basic and Clinical Science, Section 7, Orbit, Eyelids and Lacrimal System, AAO, San Francisco, page 104.
2. Hamilton A, Meena M, Lawlor M, et al. An unusual case of intraorbital foreign body and its management. Int Ophthalmol. 2014;34:337e339
3. Jia Li, Li-Ping Zhou, Jing Jin, Hong-Feng Yuan. 2016. Clinical diagnosis and treatment of intraorbital wooden foreign bodies. Chinese Journal of Traumatology 19 (2016) 322-325.
4. Kuhn F, Pieramici DJ, 2002, Ocular Trauma: Principles and Practice, Thieme, New York.
5. Miller CF, Brodkey JS, Colombi BJ. The danger of intracranial wood. Surg Neurol 1977;7:95-103.

6. Nasr AM, Haik BG, Fleming JC, Al-Hussain HM, Karciloglu ZA. Penetrating orbital injury with organic foreign bodies. *Ophthalmology* 1999;106:523-32.
7. Roos KL. Principles of neurologic infectious diseases. New York, NY: McGraw-Hill; 2005.
8. Sachin Anil Borkar, Kanwaljeet Garg, Mayank Garg , Bhawani Shankar Sharma. 2014. Transorbital penetrating cerebral injury caused by a wooden stick: surgical nuances for removal of a foreign body lodged in cavernous sinus. *Childs Nerv Syst* (2014) 30:1441–1444.
9. Schreckinger M, Orringer D, Thompson BG, La Marca F, Sagher O (2011) Transorbital penetrating injury: case series, review of the literature, and proposed management algorithm. *J Neurosurg* 114:53–61
10. Shelsta HN, Bilyk JR, Rubin PA, et al. Wooden intraorbital foreign body injuries: clinical characteristics and outcomes of 23 patients. *Ophthal Plast Reconstr Surg*. 2010;26:238e244.
11. Süleyman Taş, M.D., Hüsamettin Top, M.D. Intraorbital wooden foreign body: clinical analysis of 32 cases, a 10-year experience. *Ulus Travma Acil Cerr Derg*, January 2014, Vol. 20, No. 1