

## CASE REPORT

# Malignant Triton Tumor without Von Recklinghausen's Neurofibromatosis in a 16 year-old Indonesian Girl: A Case Report

Neni Anggraini<sup>1</sup>, Nurjati Chairani Siregar<sup>2</sup>

<sup>1</sup>Department of Ophthalmology, <sup>2</sup>Department of Anatomic Pathology  
Faculty of Medicine, Universitas Indonesia  
Cipto Mangunkusumo Hospital, Jakarta  
E-mail: neni\_anggraini@hotmail.com

## ABSTRACT

**Background:** To diagnose malignant peripheral nerve sheath tumor with rhabdomyoblastic differentiation in malignant triton tumor which has a rare incidence.

**Case Illustration:** We reported a case in a 16 year-old girl who presented with progressively painless proptosis of the left eye and decreased visual acuity. There was no evidence of Recklinghausen's disease. She underwent surgery and radiotherapy. The histopatologic findings showed malignant peripheral nerve sheath tumor (MPNST). Four years later, she suffered recurrence proptosis and decreased visual acuity. Histomorphology supported by immunostaining with S-100 protein confirmed the diagnosis of malignant triton tumor. She underwent chemotherapy and enucleation.

**Conclusion:** This case highlights the prudent use of immunohistochemistry that is essential in making an early detection and a correct diagnosis.

**Keywords:** Malignant peripheral nerve sheath tumor; Malignant triton tumor; S-100 protein

Malignant triton tumor (MTT) is a very rare and highly aggressive variant of the malignant peripheral nerve sheath tumor (MPNST), with rhabdomyoblastic differentiation<sup>1</sup>. Malignant peripheral nerve sheath tumor arises from Schwann cells or within existing neurofibromas and have a strong association with type 1 neurofibromatosis, although sporadic cases do occur. Malignant peripheral nerve sheath tumors as a group account for approximately 5% of all soft tissue sarcomas.<sup>1</sup> Malignant triton tumor usually develops in individuals at average age of

35 and is associated with a poor outcome; 5- year survival rates as low as 14%.<sup>2,3</sup> These tumors are histologically diverse and may contain malignant areas of divergent mesenchymal differentiation, the most common of which is skeletal muscle (rhabdomyosarcoma).<sup>1</sup> This is the first MTT case in Cipto Mangunkusumo Hospital Jakarta, Indonesia.

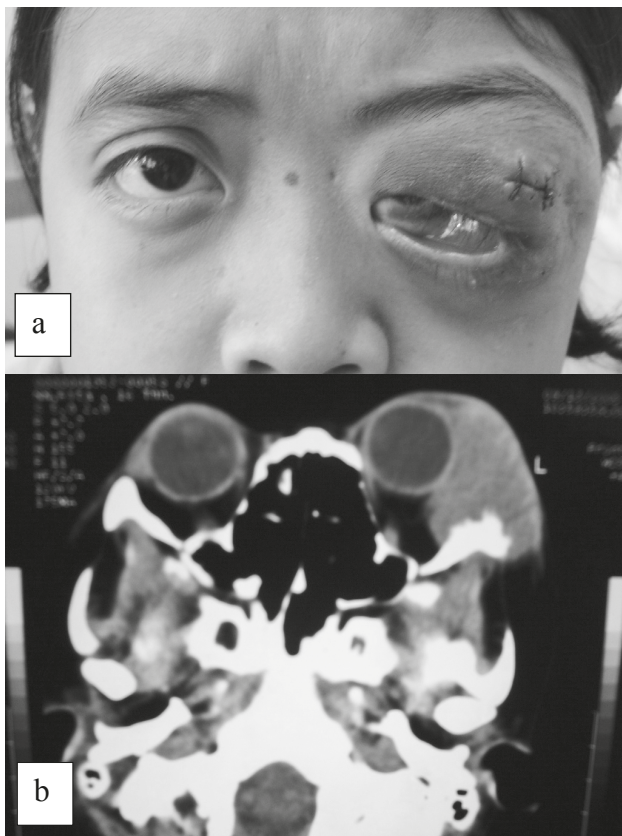
## CASE ILLUSTRATION

A 16 year-old girl was referred with a year history of progressive painless proptosis of the left eye

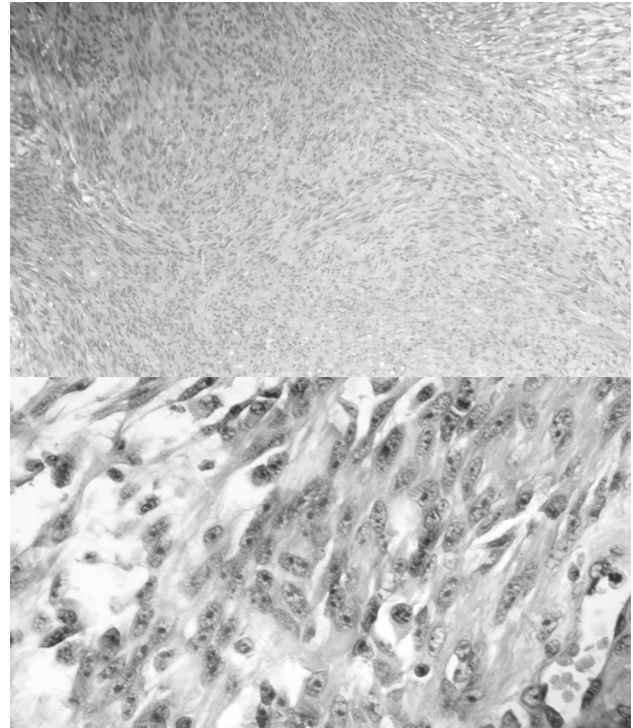
and decreased visual acuity to 4-meter finger counting. A palpable periorbital mass was found at the supero-temporal extending to inferior orbit, with ocular motility restriction, a positive relative afferent pupillary defect and a swollen optic disc (Figure 1a). There was no evidence of Von Recklinghausen's disease.

Orbital ct-scan revealed an orbital mass at the lateral and posterior site with lateral and posterior orbital wall invasion (Figure 1b). The tumor was removed totally and histopathologic findings showed a malignant peripheral nerve sheath tumor (MPNST) or malignant schwannoma.

Six weeks later she received postoperative 6000 cGy external beam radiotherapy. Three months post radio-therapy, there were radiodermatitis, severe dry eyes and decreased visual acuity to 1-m finger counting due to corneal opacity and neovascularization. There was no progression of intraorbital tumor and metastasis at six months follow-up. Several plastic reconstructive surgeries were done to manage the acquired ptosis and ectropion post radiotherapy.



**Fig 1.** Picture of the patient, showing left proptosis (a), and axial image of CT scan examination (b)



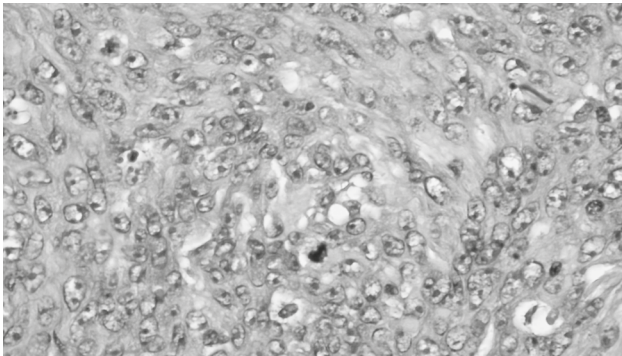
**Fig 2.** Overall picture of malignant peripheral nerve sheath tumor. Malignant spindle cells with marked pleomorphism and fasciculated architecture are seen (hematoxylin-eosin, original magnification x 100 and x 400).

Four years later the patient suffered recurrence proptosis and decreased visual acuity to hand movement. The CT-Scan examination revealed a left orbital proptosis due to an orbital mass expansion at the lateral orbital cone with orbital bone destruction. A lateral transconjunctival incisional biopsy was done and this time histopathologic result was grade III anaplastic rhabdomyosarcoma, a variant of embryonal rhabdomyosarcoma. After a thorough review, the final histopathologic findings supported the diagnosis of MPNST with rhabdomyoblastic differentiation or malignant triton tumor. Chemotherapy was given which resulted in tumor size reduction. Although there were still orbital walls destruction, the proptosis was no longer noted. Due to cosmetic reasons, the patient opted for enucleation of the left eye.

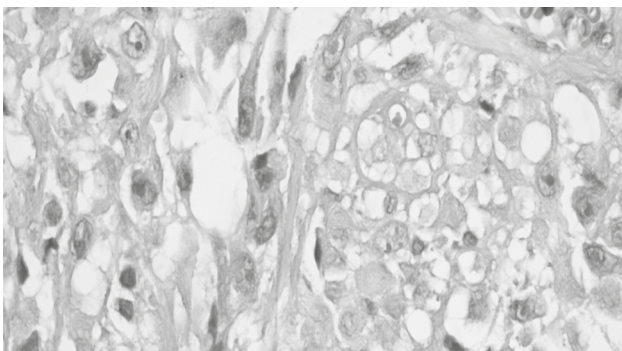
## DISCUSSION

A malignant peripheral nerve sheath tumor often arises in the clinical setting of Neurofibromatosis type 1 (NF1), although sporadic cases do occur.<sup>1</sup>

These tumors may also arise in the sites of previous irradiation.<sup>1</sup> In this case, we found no evidence of family history and physical sign of Neurofibromatosis type 1 or von Recklinghausen's disease, such as cutaneous nodules nor café-au-lait spots of the skin.



**Fig 3.** Increased mitotic activity was found (hematoxylin-eosin, original magnification x 400).



**Fig 4.** Malignant peripheral nerve sheath tumor with rhabdomyoblastic differentiation (malignant triton tumor). Rounded and elongated cells with eosinophilic cytoplasm (arrows) morphologically consistent with rhabdoid differentiation are identified in a background of classic malignant peripheral nerve sheath tumor (hematoxylin-eosin, original magnification x 400).

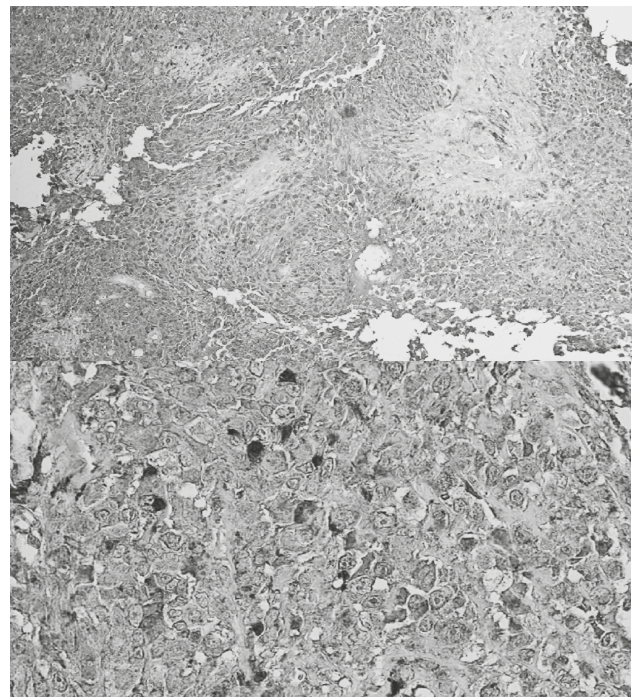
Thus, sporadic origin may be thought of for the present case. On the other hand, the age of the present case didn't match with literature that stated triton tumor without Recklinghausen's disease usually found in older age and predominantly female patients.<sup>4</sup>

In gross examination, MPNST is a firm tumor and may either appear pseudoencapsulated or have ill-defined margins. The tumor may grow along adjacent nerves or infiltrate nearby soft tissue. Foci of hemorrhage and necrosis may be seen.<sup>1</sup>

Traditionally, MPNST has been among the most challenging soft tissue tumor diagnoses to be determined because of the lack of standard histologic criteria. The tumor is composed of hyperchromatic

spindle cells growing in a fasciculated pattern. The cytoplasm is typically light staining and indistinct. The overall architecture may be either diffuse or arranged in alternating hypocellular and densely cellular areas<sup>1</sup> (figure 2). High-grade tumors usually contain necrosis and increased mitotic activity<sup>1</sup> (figure 3).

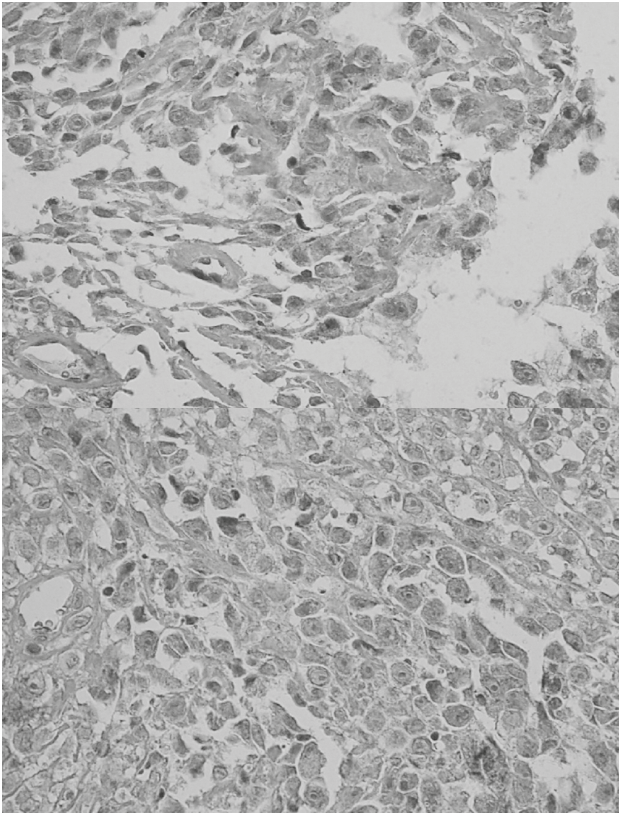
The capacity of MPNSTs to undergo focal mesenchymal differentiation is well known, which is sarcomatous in nature and histologically malignant. Rhabdomyosarcoma (MTT) is the most frequently encountered example of divergent differentiation in MPNST<sup>1</sup> (Figure 4).



**Fig 5.** Strong positive cytoplasmic of S100 staining is noted in spindle cells (arrows) malignant peripheral nerve sheath tumor (original magnification x 100 and x 400).

Immunohistochemically, S100 protein is positive in 50% to 90% of MPNSTs, with Leu-7 and myelin basic protein positivity being useful adjuncts. S100 staining is focal and only present in a minority of the cells.<sup>1</sup> The morphologic suspicion of rhabdoid/skeletal muscle differentiation may be confirmed with positive staining with desmin, myogenic differentiation, muscle-specific actin, and myogenin.

This case revealed a strong positive S100 staining which proved that this is a MPNST (Figure 5). A positive result also showed in desmin staining (Figure 6).



**Figure 6.** Positive cytoplasm Immunohisto-chemical staining with desmin is noted in rhabdomyoblastic cells (arrows) in malignant peripheral nerve sheath tumor (original magnification x 400).

## CONCLUSION

Malignant peripheral nerve sheath tumor or malignant schwannoma may contain malignant areas of divergent mesenchymal differentiation, the most common of which is skeletal muscle (rhabdomyosarcoma). Malignant peripheral nerve sheath tumor with rhabdomyoblastic differentiation is also known as malignant triton tumor. The prudent use of immunohistochemistry is essential in establishing a correct diagnosis.

## REFERENCES

1. Statik CJ, Tawfik O. Malignant peripheral nerve sheath tumor with rhabdomyosarcomatous differentiation (malignant triton tumor). *Arch Pathol Lab Med* 2006;130:1878-81.
2. Mae K, Kato Y, Usui K, Abe N, Tsuboi R. A case of Malignant Peripheral Nerve Sheath Tumor with Rhabdomyoblastic Differentiation: Malignant Triton Tumor. *Case Rep Dermatol* 2013;5:373-378
3. McConell YJ, Giaucantonio CA. Malignant Triton Tumors-complete surgical resection and adjuvant radiotherapy associated with improved survival. *J. Surg. Oncol.* 2012; 106:51-56.
4. Tripathy K e al. A Rare Malignant Triton Tumor. *Case Rep Neurol* 2010;2:69-73