

ORIGINAL ARTICLE

EFFECT OF BLOOD GLUCOSE CONTROL TOWARDS PLASMA AND VITREOUS LEVELS OF VASCULAR ENDOTHELIAL GROWTH FACTOR AND PLACENTAL GROWTH FACTOR IN DIABETIC RATS

Anggun Rama Yudantha¹, Nina Asrini Noor¹, Joedo Prihartono^{1,2}

¹Department of Ophthalmology, Faculty of Medicine Universitas Indonesia, Cipto Mangunkusumo National Hospital, Jakarta, Indonesia

²Department of Public Health and Community Medicine, Faculty of Medicine Universitas Indonesia, Jakarta, Indonesia

Email: nina.asrini.noor@gmail.com

ABSTRACT

Purpose: To compare plasma and vitreous level of vascular endothelial growth factor (VEGF) and placental growth factor (PlGF) in diabetic rats with poor blood glucose (BG) control, reconstitution of good BG control, and nondiabetic rats, and to investigate the effect of reconstitution of good BG control to VEGF and PlGF plasma and vitreous level.

Methods: This is an experimental study using eighteen Sprague Dawley rats which were divided into intervention group (n=14) and control group (n=4). Intervention group were given Streptozotocin (STZ) injection to induce diabetes. After 4 weeks, intervention group was randomly divided into group I for termination and group II for reconstitution of good BG control with insulin for the following 4 weeks, and so was the control group. Plasma and vitreous samples were taken. VEGF and PlGF levels were evaluated with enzyme-linked immunosorbent assay (ELISA).

Results: Seventeen of 18 rats survived in intervention group. BG level of intervention group II decreased dramatically to normoglycemia. ELISA at month 1 showed that VEGF vitreous level tend to be higher in intervention group I compared to control I, 196.36 ± 65.24 pg/dL and 123.64 ± 44.99 , respectively ($p=0.20$). ELISA at month 2 showed that PlGF vitreous level of intervention group I were significantly higher compared to control I, 59.04 ± 2.48 and 51.93 ± 3.15 , respectively ($p=0.01$). Vitreous and plasma VEGF of intervention group I and II were not different, while vitreous and plasma PlGF were significantly higher in group II.

Conclusions: Vitreous levels of VEGF and PlGF were increased in diabetic rats compared to nondiabetic, and reconstitution of good BG control for 1 month were unable to reduce VEGF and PlGF levels.

Keywords: diabetic rat models, placental growth factor, vascular endothelial growth factor, vitreous

INTRODUCTION

Diabetes mellitus is a metabolic syndrome with massive global burden. The incidence of diabetes mellitus has increased dramatically from 171 million to approximately 366 million in 2030.¹ Diabetic retinopathy is the primary microvascular complication and one of

the major leading cause of blindness.^{2,3} A comprehensive study by Yau et al showed that the prevalence of diabetic retinopathy has reached 35%.⁴

Hyperglycemia holds an important role in the pathogenesis of diabetic retinopathy and tight metabolic control is still a mainstay in the management of diabetic retinopathy.⁵ Diabetes Control and Complication Trial (DCCT) showed that intensive control decreased the risk of developing diabetic retinopathy as much as 76% and slowed down the progression in 54% patients with type 1 diabetes mellitus.⁶ Nevertheless, a study by Warboys et al showed that increased level of blood glucose did not directly cause functional and cellular change in the progression of diabetic retinopathy.⁷

Vascular endothelial growth factor (VEGF) is one of many growth factors involved in the pathogenesis of diabetic retinopathy.⁸⁻¹⁰ Increased concentration of VEGF in the vitreous of patients with diabetic retinopathy has been shown in various studies.^{11,12} Placental growth factor (PIGF), which has been proven to have a role in diabetic retinopathy, is a homolog of VEGF which binds to the same receptor and works synergistically with VEGF to induce angiogenesis.^{13,14} In proliferative diabetic retinopathy, concentration and mRNA expression of PIGF is shown to increase.¹⁵

Metabolic control may reduce the risk of diabetic retinopathy in diabetes mellitus. However, good blood glucose control seems to incompletely prevent the incidence or slow down the progression of diabetic retinopathy. Regarding PIGF, there is no published data of how blood glucose control may affect its concentration in the vitreous or systemic circulation. From these considerations, we would like to know whether reconstitution of good blood glucose control affect VEGF and PIGF level in the vitreous and systemic circulation in diabetic rats.

MATERIAL AND METHODS

This study was approved by the Ethics Committee of the Faculty of Medicine, University of Indonesia with ethical approval number 354/UN2.F1/ETIK/2016. Eighteen healthy adult male Sprague Dawley rats with weight 230-280 g were purchased from Animal Laboratorium of *Pusat Penelitian Biomedis Badan Penelitian dan Pengembangan Kesehatan*. All rats were randomly divided into two groups, 14 rats in intervention group and 4 rats in control groups. These rats were housed in 5 separate cages. This study was carried out in adherence to recommendations of resolution for the use of animal in ophthalmic and vision research by The Association for Research in Vision and Ophthalmology (ARVO).

In order to induce diabetes, each rat in intervention group was treated with a single intraperitoneal injection of streptozotocin (STZ, 50 mg/kg; Sigma Aldrich Inc). This was

followed by blood glucose examinations from the tail veins using blood glucometer (Accu-chek Active, Roche). All 14 rats in intervention group had blood glucose level more than 300 mg/dL in three days after injection, were diagnosed with diabetes, and enrolled in this study. In control group, all 4 rats were not treated with any intervention.

Blood glucose level were recorded daily in all the rats of intervention group and once a week in all the rats of control group. Periods of observation and intervention were one month and two months after injection. All rats in intervention group will be observed for the initial one month in the condition of poor blood glucose control. After four weeks, all the rats in intervention group were further divided into intervention group I and II. Intervention group I was terminated at the end of the first month, while intervention group II was given intervention for the reconstitution of good blood glucose control for another month. All the rats of control group were also randomly divided into two groups to have separate time of termination.

During the first month, all rats in intervention group received subcutaneous injection of short-acting insulin (Actrapid® human mono-component insulin, Novo Nordisk) if the blood glucose level exceeded 400 mg/dL. During the second month, rats in intervention group II were regularly treated with subcutaneous injection of long-acting insulin (Lantus® insulin glargine, Sanofi) twice daily to achieve blood glucose level lower than 200 mg/dL.

Termination of all rats were performed under the recommendations of Institutional Animal Care and Use Committee Guidelines. To collect blood samples, vena cava aspiration was performed, and 2 mL of whole blood was collected in EDTA tubes. Plasma was separated from other blood components and was further centrifugated at 3000 revolution per minute for 15 minutes followed by ELISA of VEGF and PlGF. To collect vitreous samples, all eyeballs were enucleated, and vitreous bodies were aspirated and kept in eppendorf tubes. Vitreous samples were centrifugated at 3000 revolution per minute for 10 minutes followed by ELISA of VEGF and PlGF. All ELISA examinations were performed using a specific kit for rats (Abbexa Ltd.) and in duplo.

Statistical analysis and graphics were done using IBM SPSS 20.0 (SPSS Inc., Chicago, IL). The results were presented as mean \pm SD or median(range) according to the distribution of the data, and percentages. Statistical significance was defined as $p < 0.05$.

RESULTS

Mean initial blood glucose level of intervention group and control group were not different, 75.71 ± 6.13 mg/dL and 80.25 ± 7.41 mg/dL, respectively ($p=0.23$). Diabetes developed in all rats in intervention group on the third day after injection with mean blood

glucose level 442.86 ± 80.50 mg/dL and was significantly different compared to initial level ($p < 0.01$). One rat died in intervention group and was dropped out from the study. After four weeks, all rats in intervention group were randomly divided in group I which consisted of 6 rats and group II which consisted of 7 rats. All rats in control group were also divided into two groups and each consisted of two rats.

Comparison of blood glucose level of intervention group II and control group II is shown in table 1. Blood glucose level of intervention group was significantly reduced into a level of lower than 200 mg/dL in month 2 compared to initial concentration in month 1 which was higher than 400 mg/dL. Their blood glucose levels were even significantly lower than those of control group.

Table 1 Comparison of blood glucose level between intervention group II and control group II during month 1 and 2

| | Blood glucose level month 1 (mg/dL) | Blood glucose level month 2 (mg/dL) | p value |
|-----------------------|-------------------------------------|-------------------------------------|---------|
| Intervention II (n=7) | 414.50 (226-600) | 65.00 (35-365) | <0.01b |
| Control II (n=2) | 103.13 \pm 10.86 | 108.63 \pm 12.69 | 0.41c |
| p value | <0.01a | <0.01a | |

Notes: ^aMann-Whitney test; ^bWilcoxon test; ^cPaired T test

Changes of blood glucose level in all groups is shown in figure 1. At the end of the first month, blood glucose level of intervention group I and II were similar and consistent above 350 mg/dL. At the end of the second month, blood glucose levels of intervention group II were markedly reduced to a condition lower than control group.

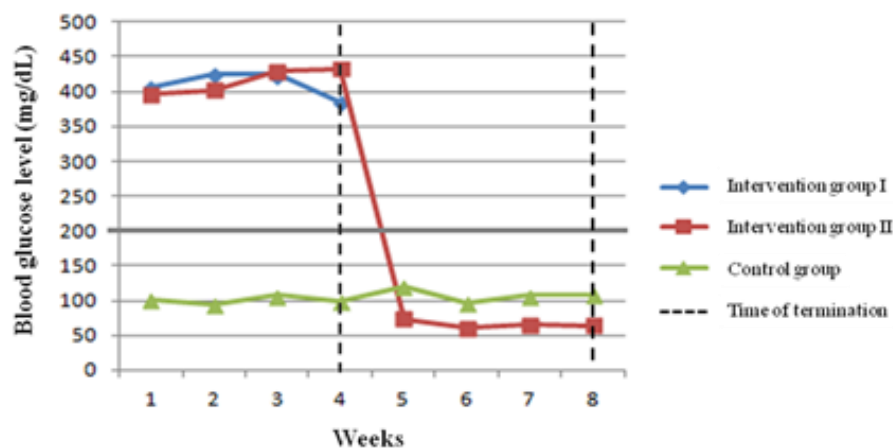


Figure 1 Changes of blood glucose levels between intervention group I and II compared to control group

Comparison of vitreous and plasma level of VEGF and PIGF in intervention group and control group at month 1 is shown in table 2. Vitreous VEGF level of intervention group was higher than control group, although this difference was not proven to be statistically significant. Plasma VEGF levels of intervention and control group showed similar results. Vitreous VEGF levels of both groups were higher than plasma levels, while opposite findings were found in PIGF levels.

Table 2 Comparison of vitreous and plasma levels of VEGF and PIGF between intervention group I and control group I

| | Intervention I (n=6) | Control I (n=2) | p value |
|--------------|----------------------|-----------------|---------|
| VEGF (pg/mL) | | | |
| Vitreous | 196.36 ± 65.24 | 123.64 ± 44.99 | 0.20a |
| Plasma | 93.34 ± 25.17 | 94.09 ± 3.21 | 0.97a |
| PIGF (pg/mL) | | | |
| Vitreous | 50.86 ± 3.48 | 48.59 ± 0.88 | 0.42a |
| Plasma | 57.83 ± 5.96 | 65.18 ± 18.73 | 0.68a |

Notes: ^aStudent T test

Consistent with the findings during the first month, vitreous VEGF and PIGF levels of intervention group were higher than control group (table 3). However, the differences were significant only for PIGF and not for VEGF. Also similar with the findings at month 1, vitreous VEGF levels were higher than plasma levels, while opposite results were found in PIGF levels.

Table 3 Comparison of vitreous and plasma levels of VEGF and PIGF between intervention group II and control group II

| | Intervention II (n=7) | Control II (n=2) | p value |
|--------------|-----------------------|------------------|---------|
| VEGF (pg/mL) | | | |
| Vitreous | 195.71 ± 55.27 | 173.64 ± 25.72 | 0.61a |
| Plasma | 113.90 ± 35.92 | 96.37 ± 19.28 | 0.54a |
| PIGF (pg/mL) | | | |
| Vitreous | 59.04 ± 2.48 | 51.93 ± 3.15 | 0.11a |
| Plasma | 111.09 ± 53.11 | 108.99 ± 53.03 | 0.96a |

Notes: ^aStudent T test

The differences of vitreous and plasma VEGF levels in both intervention groups were not shown to be statistically significant, as seen in table 4, although treatment had been given to intervention group II. Opposite results were seen in vitreous and plasma PIGF levels. Intervention group II showed higher vitreous and plasma PIGF levels compared to group I.

Reconstitution of good control did not seem to affect VEGF levels but showed an increase in PIGF levels.

Table 4 Comparison of VEGF and PIGF levels between intervention groups

| | Intervention group | | p value |
|------------------|----------------------|-----------------------|--------------------|
| | Intervention I (n=6) | Intervention II (n=7) | |
| VEGF | | | |
| Vitreous (pg/mL) | 196.36 ± 65.24 | 195.71 ± 55.27 | 0.99 ^a |
| Plasma (pg/mL) | 93.34 ± 25.17 | 113.90 ± 35.92 | 0.27 ^a |
| PIGF | | | |
| Vitreous (pg/mL) | 50.86 ± 3.48 | 59.04 ± 2.48 | <0.01 ^a |
| Plasma (pg/mL) | 57.83 ± 5.96 | 111.09 ± 53.11 | 0.04 ^a |

Notes: ^aStudent T test

Comparison of both growth factor levels in plasma and vitreous of each observation period is shown in figure 2. As seen in figure 2A, there is a considerable difference between vitreous VEGF levels of intervention group and control group. Vitreous VEGF levels of intervention group I and II were not different ($p=0.99$), while plasma VEGF levels were similar between all intervention and control groups. In figure 2B, at month 1 vitreous and plasma PIGF levels were similar, while at month 2 there was a significant difference of vitreous PIGF levels between the two intervention groups ($p<0.01$). A significant difference was also seen in plasma PIGF levels between intervention group ($p=0.04$) however when compared to control group the difference was not significant ($p=0.96$).

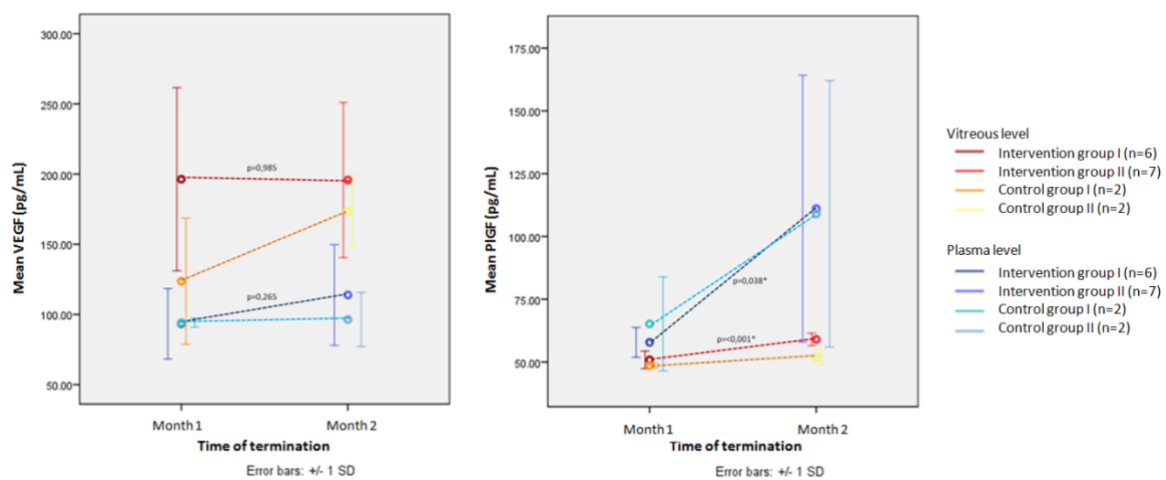


Figure 2 Comparison of VEGF (A) and PIGF (B) PIGF levels of vitreous and plasma between intervention group and control group at month 1 and 2

DISCUSSION

Diabetes mellitus causes microvascular and macrovascular changes due to neovascular mechanism.¹⁶ Excessive angiogenesis in diabetes takes the role the diabetic retinopathy. Diabetic retinopathy is a multifactorial complication attributable to complex interaction between biochemical and metabolic abnormalities in the retina. Multiple cellular pathway activities mediated by hyperglycemia suggested to have an important role in the pathogenesis of diabetic retinopathy. Hyperglycemia causes biochemical changes which induce increased regulation of proangiogenic and inflammatory factors. The imbalance between proangiogenic and antiangiogenic factors causes blood retinal barrier damage and growth of new vessels in diabetic retinopathy.

This study utilized Sprague Dawley rats which were given 50 mg/kg intraperitoneal Streptozotocin injection to induce diabetes. Previous studies using the same strain of rats used various dosage of STZ ranging from 45 mg/kg to 70 mg/kg according to baseline range of body weight.^{17,18} The onset of diabetes itself ranges from 1 to 3 days after injection which is similar to our study in which all rats were diagnosed as diabetes within 3 days after injection.^{17,18}

During the first month, all rats in intervention groups were in uncontrolled hyperglycemia condition. Mean blood glucose level for 4 weeks was above 400 mg/dL consistently. Similar result was found in other study in which 42 diabetic rats had mean blood glucose level above 450 mg/dL for four weeks.¹⁹ To achieve reconstitution of good blood glucose level in intervention group II during the second month, rats were given subcutaneous injection of long acting insulin Lantus® daiy as recommended by Luippold et al in their study.²⁰ The applied dosage was 4 IU considering achievement of normoglycemia with this dosage. There were three events found in our study. First, the tendency of increased vitreous VEGF levels but not in plasma and not in PIGF in the first month. Second, the constant levels of VEGF in the vitreous and plasma accompanied by increased levels of PIGF in vitreous and plasma after reconstitution of good control. And third, the contradictory ratio between vitreous and plasma VEGF and PIGF in which vitreous VEGF levels were consistently higher than plasma levels while opposite finding was found in PIGF.

In this study we found a tendency of increased VEGF levels in the vitreous of diabetic rats within 1 month after uncontrolled hyperglycemia compared to healthy rats. According to several studies, VEGF within the eye is mainly a result of local production.²¹⁻²³ VEGF is produced by cells as an unbound molecule which can bind to its receptor. The result of this study was similar to study by Zhang et al and Sueshi et al which found an increase of vitreous

VEGF levels and its protein expression within the retina of diabetic rats.^{19,24} VEGF expression in diabetes is caused by increased production of reactive oxygen species (ROS) which further increase VEGF mRNA stability.^{25,26} Increased VEGF regulation in early diabetic retinopathy is not merely compensation towards hypoxia and ischemia, although hypoxia is a major stimulator for VEGF production.

In contrast to VEGF, vitreous level of PlGF in our study did not show an increase compared to healthy nondiabetic rats. PlGF is expressed as a response to hypoxia and other growth factors involved in angiogenesis.^{14,27} Unlike VEGF, hypoxia is not the main stimulator towards PlGF. Without severe hypoxia, PlGF is already produced in early diabetic retinopathy.²⁸ In addition, PlGF exclusively binds to VEGFR-1 with higher affinity compared to VEGF. VEGFR-1 are naturally expressed by healthy tissue and various cell types including endothelial cells and mononuclear cells compared to VEGFR-2 which are solitarily expressed by endothelial cells in pathological condition.^{29,30} For this reason, it may come to consideration that PlGF previously produced will directly bind to VEGFR-1 and the unbound molecules will be detected as being stable or not increased.

Plasma levels of both VEGF and PlGF were not increased in our diabetic rats at the end of the first month. Diabetes initially causes microvasculature damage which is more vulnerable towards hypoxia. VEGF is found to be increased in diabetic microvascular complications such as retinopathy, nephropathy, and neuropathy. The increase of VEGF levels were found to be local.³¹ In long-standing diabetes accompanied by macrovascular complications, almost all organs are affected, therefore systemic VEGF may be increased.

Another finding in this study was seen after reconstitution of good control at the end of the second month. Reconstitution of good control for 1 month may be assumed to only inhibit further increase of VEGF levels but did not reverse to normal condition. Chiarelli et al in the study found decreased serum VEGF levels in diabetic patients after 2 years of good blood glucose control.³² In other words, reconstitution of good control may require longer period of time to reverse growth factor levels. Another possible justification is related to the binding of VEGF to VEGFR-2. VEGF production may not be entirely inhibited but the unbound molecules binds to VEGFR-2 which expression are increased due to the high level of VEGF itself. Eventually, VEGF levels were detected as if they did not increase.

In contrast to VEGF, systemic and local PlGF levels continued to increase after reconstitution of good control. One possible reason is reconstitution of good control may inhibit VEGF production but not PlGF. Diabetic microvascular complications cause hypoxia and retinal ischemia.³³ Increased PlGF regulation is not solely stimulated by hypoxia but also other

stimuli including nitric oxide, cytokines, and other growth factor.^{34,35} Second, all VEGFR-1 as the exclusive receptor bind to PIGF, therefore unbound molecules of PIGF will be detected as increased. A study by Gilbert et al supports this study which found VEGFR-1 distribution were not increased in diabetes.³⁶ Last possible explanation is that VEGF has the ability to increase PIGF regulation.³⁷

Last finding in our study is the contradictory ratio between vitreous and plasma VEGF and PIGF. Vitreous VEGF levels were consistently higher than plasma levels. This result is similar with study by Wang et al and Qian et al who stated that vitreous VEGF levels were higher than serum levels in patient with proliferative diabetic retinopathy.^{21,38} VEGFR-2 expression is higher in capillary endothelial cells compared to larger vessels. This explains increased regulation of VEGF and VEGFR in diabetes initially occurred in capillary bed.³⁹ This finding support the viewpoint that increased vitreous VEGF levels are due to local production. Opposite result was found in PIGF which plasma levels were consistently higher than vitreous levels. As far to our knowledge, there is no study directly comparing systemic and vitreous PIGF levels in patient with diabetes or diabetic retinopathy. Studies by Mitamura et al and Khaliq et al showed vitreous PIGF levels in proliferative diabetic retinopathy were approximately 100 pg/mL, while separate study by Helske et al in patient with diabetes showed serum PIGF levels were as high as 690 ± 423 pg/ml.^{13,15,40} This finding suggests that systemic PIGF levels are higher than vitreous levels but the basic mechanism needs to be elucidated.

This study has several limitations. First, relatively short period of observation. With longer observation difference between intervention and control group, and also between poor control and reconstitution of good control, may be more apparent. Second, method of blood glucose evaluation may be improved by performing examination more than once a day to observe any blood glucose fluctuation. Blood glucose control using insulin implants or Linplant® may also be considered. And third, ELISA did not evaluate intraretinal levels of growth factor and only assessed the unbound levels.

CONCLUSION

GDD implantation provided good outcomes in NVG management in terms of IOP control and reduction of antiglaucoma medications. GDD implantation combined with IVB injection might offer the potential in maintaining VA compared to GDD alone despite IOP control and number of medications remained the same. Prospective study with larger sample size and longer period of follow up is warranted. IVB injection protocol should also be standardized to confirm efficacy and safety of this treatment modality.

REFERENCES

1. Rathmann W and Giani G. Global prevalence of diabetes: estimates for the year 2000 and projections for 2030. *Diabetes Care*. 2005;27:2568-2569.
2. Jain A, Saxena S, Khanna VK, Shukla RK, Meyer CH. Status of serum VEGF and ICAM-1 and its association with external limiting membrane and inner segment-outer segment junction disruption in type 2 diabetes mellitus. *Mol Vis*. 2013;4(19):1760-1768.
3. Stitt AW, Lois N, Medina RJ, Adamson P, Curtis TM. Advances in our understanding of diabetic retinopathy. *Clin Sci (Lond)*. 2013;125(1):1-17.
4. Yau JW, Rogers SL, Kawasaki R, Lamoureux EL, Kowalski JW, Bek T, et al. Global prevalence and major risk factors of diabetic retinopathy. *Diabetes Care*. 2012;35:556-564.
5. Nilsson PM. ACCORD and risk-factor control in type 2 diabetes. *N Engl J Med*. 2010;362:1628-1630.
6. Diabetes Control and Complications Trial Research Group. The effect of intensive treatment of diabetes on the development and progression of long-term complications in insulin-dependent diabetes mellitus. *N Engl J Med*. 1993;329:977-986.
7. Warboys CM, Fraser PA. Hyperglycemia attenuates acute permeability response to advanced glycation end products in retinal microvasculature. *Microvascul Res*. 2010;80:174-176.
8. Pe'er J, Folberg R, Itin A. Upregulated expression of vascular endothelial growth factor in proliferative diabetic retinopathy. *Br J Ophthalmol*. 1996;80:241-245.
9. Romero-Aroca P. Managing diabetic macular edema: The leading cause of diabetes blindness. *World J Diabetes*. 2012;2:98-104.
10. Funatsu H, Yamashita H, Noma H, Mimura T, Yamashita T, Hori S. Increased levels of vascular endothelial growth factor and interleukin-6 in the aqueous humor of diabetics with macular edema. *Am J Ophthalmol*. 2002;133(1):70-77.
11. Funatsu H, Yamashita H, Noma H, Shimizu E, Yamashita T, Hori S. Stimulation and inhibition of angiogenesis in diabetic retinopathy. *Jpn J Ophthalmol*. 2001;45:577-584.
12. Mohan N, Monickaraj F, Balasubramanyam M, Rema M, Mohan V. Imbalanced levels of angiogenic and angiostatic factors in vitreous, plasma and postmortem retinal tissue of patients with proliferative diabetic retinopathy. *J Diabetes Complications*. 2012;26:435-441.
13. Mitamura Y, Tashimo A, Nakamura Y, Tagawa H, Ohtsuka K, Mizue Y, Nishihira J. Vitreous levels of placenta growth factor and vascular endothelial growth factor in patients with proliferative diabetic retinopathy. *Diabetes Care*. 2002;25(12):2352.
14. Carmeliet P, Moons L, Luttun A, Vincenti V, Compernelle V, Mol MD, et al. Synergism between vascular endothelial growth factor and placental growth factor contributes to angiogenesis and plasma extravasation in pathological conditions. *Nat Med*. 2001;7:575-583.
15. Khaliq A, Foreman D, Ahmed A, Weich H, Gregor Z, McLoad D, Boulton M. Increased expression of placenta growth factor in proliferative diabetic retinopathy. *Lab Invest*. 1998;78:109-116.
16. Simons M. Angiogenesis, arteriogenesis, and diabetes, paradigm reassessed? *J Am Coll Cardiol*. 2005;46(5):835-7.
17. Ye X, Xu G, Chang Q. ERK1/2 signaling pathways involved in VEGF release in diabetic rat retina. *Invest Ophthalmol Vis Sci*. 2010;51(10):5226-5233.
18. Zhang X, Chen M, Gillies MC. Two isoforms of Flk-1 transcripts in early diabetic rat retinas. *Curr Eye Res*. 2012;37(1):73-79.
19. Zhang Y, Song D, Zhang G. Study on vascular endothelial growth factor and its receptor in the vitreous of diabetic rats. *West Indian Med J*. 2013;62(9):799-802.
20. Luippold G, Bedenik J, Voigt A, Grempler R. Short- and Longterm Glycemic Control of Streptozotocin-Induced Diabetic Rats Using Different Insulin Preparations. *PLoS One*. 2016;11(6): e0156346.
21. Wang X, Wang G, Wang Y. (2009). Intravitreal vascular endothelial growth factor and hypoxia-inducible factor 1a in patients with proliferative diabetic retinopathy. *Am J Ophthalmol*, 148(6), 883-889.
22. Ma Y, Zhang Y, Zhao T, Jiang YR. Vascular endothelial growth factor in plasma and vitreous fluid of patients with proliferative diabetic retinopathy patients after intravitreal injection of bevacizumab. *Am J Ophthalmol*. 2012;153(2):307-313.
23. Gupta N, Mansoor S, Sharma A, Sapkal A, Sheth J, Falatoonzadeh P, et al. Diabetic Retinopathy and VEGF. *Open Ophthalmol J*. 2013;7:4-10.
24. Sueishi K, Hata Y, Murata T, Nakagawa K, Ishibashi T, Inomata H. Endothelial and glial cell interaction in diabetic retinopathy via the function of vascular endothelial growth factor (VEGF). *Pol J Pharmacol*. 1996;48(3):307-316.
25. Hammes HP, Lin J, Bretzel RG, Brownlee M, Breier G. Upregulation of the vascular endothelial growth factor/vascular endothelial growth factor receptor system in experimental background diabetic retinopathy of the rat. *Diabetes*. 1998;47(3):401-406.

26. Kuroki M, Voest EE, Amano S, Beerepoot LV, Takashima S, Tolentino M, et al. Reactive oxygen intermediates increase vascular endothelial growth factor expression in vitro and in vivo. *J Clin Invest.* 1996;98:1667-1675.
27. Ohno-Matsui K, Yoshida T, Uetama T, Mochizuki M, Morita I. Vascular endothelial growth factor upregulates pigment epithelium-derived factor expression via VEGFR-1 in human retinal pigment epithelial cells. *Biochem Biophys Res Commun.* 2003;303:962-967.
28. Kowalczyk L, Touchard E, Omri S, Jonet L, Klein C, Valamanes F, et al. Placental Growth Factor Contributes to Micro-Vascular Abnormalization and Blood-Retinal Barrier Breakdown in Diabetic Retinopathy. *PLoS One.* 2011;6(3):e17462.
29. Neufeld G, Cohen T, Gengrinovitch S, Poltorak Z. Vascular endothelial growth factor (VEGF) and its receptor. *FASEB J.* 1999;13(1):9-22.
30. Witmer AN, Blaauwgeers HG, Weich HA, Alitalo K, Vrensen GF, Schlingemann RO. Altered expression patterns of VEGF receptors in human diabetic retina and in experimental VEGF-induced retinopathy in monkey. *Invest Ophthalmol Vis Sci.* 2002;43(3):849-857.
31. Zehetner C, Kirchmair R, Kralinger M, Kieselbach G. Correlation of vascular endothelial growth factor plasma levels and glycemic control in patients with diabetic retinopathy. *Acta Ophthalmol.* 2013;91(6): e470-473.
32. Chiarelli F, Santilli F, Mohn A. Role of growth factors in the development of diabetic complications. *Horm Res.* 2000;53(2):53-67.
33. Mahdy RA, Nada WM, Hadhoud KM, El-Tarhony SA. The role of vascular endothelial growth factor in the progression of diabetic vascular complications. *Eye (Lond).* 2010;24(10):1576-1584.
34. Ando R, Noda K, Namba S, Saito W, Kanda A, Ishida S. Aqueous humour levels of placental growth factor in diabetic retinopathy. *Acta Ophthalmol.* 2014;92(3):e245-246.
35. Hollborn M, Tenckhoff S, Seifert M. Human retinal epithelium produces and responds to placenta growth factor. *Graefes Arch Clin Exp Ophthalmol.* 2006;244:732-741.
36. Gilbert RE, Vranes D, Berka JL, Kelly DJ, Cox A, Wu LL, et al. Vascular endothelial growth factor and its receptors in control and diabetic rat eyes. *Lab Invest.* 1998;78(8):1017-1027.
37. Park JE, Chen HH, Winer J, Houck KA, Ferrara N. Placenta growth factor. Potentiation of vascular endothelial growth factor bioactivity, in vitro and in vivo, and high affinity binding to Flt-1 but not to Flk-1/KDR. *J Biol Chem.* 1994;269:25646-25654.
38. Qian J, Lu Q, Tao Y, Jiang YR. Vitreous and plasma concentrations of apelin and vascular endothelial growth factor after intravitreal bevacizumab in eyes with proliferative diabetic retinopathy. *Retina.* 2011;31(1):161-168.
39. Sun D, Nakao S, Xie F, Zandi S, Bagheri A, Kanavi MR, et al. Molecular imaging reveals elevated VEGFR-2 expression in retinal capillaries in diabetes: a novel biomarker for early diagnosis. *FASEB J.* 2014;28(9):3942-3951.
40. Helseke S, Vuorela P, Carpén O, Hornig C, Weich H, Halmesmäki E. Expression of vascular endothelial growth factor receptors 1, 2 and 3 in placentas from normal and complicated pregnancies. *Mol Hum Reprod.* 2001;7(2):205-210.