

CASE REPORT

**CHALLENGES IN MANAGEMENT OF ENDOGENOUS
ENDOPHTHALMITIS IN CHILDREN: A CASE SERIES****Eko Parulian¹, Lukman Edwar²**¹*Residence of Ophthalmology Program, Faculty of Medicine Universitas Indonesia, Cipto Mangunkusumo Hospital, Jakarta*²*Infection and Immunology Division, Department of Ophthalmology, Faculty of Medicine Universitas Indonesia, Cipto Mangunkusumo Hospital, Jakarta*

Email : ekoparuliantujuh@gmail.com

ABSTRACT

Introduction: Endophthalmitis is one of the most feared disease in ophthalmology because it can lead to loss of vision and loss of the eyeball. Endophthalmitis from endogenous cause are very rarely found in young patients without immunocompromised condition, making it difficult to be diagnosed. The lack of established guidelines for treating endogenous endophthalmitis also presents challenges for ophthalmologist. In this case series, we present our management of two pediatric patients with different presentations of endogenous endophthalmitis. We manage to salvage both of the patient's eye ball with two different approaches.

Case Report: Our first patient was a 2-years-old boy with a chief complaint red eye since 10 days before admission. He was previously diagnosed with conjunctivitis. On admission the left eye was not very inflamed but we found hypopyon and vitreous haze from ultrasound, suggestive of endophthalmitis. We gave the patient systemic antibiotics and did irrigation/aspiration of the anterior chamber. He responded well to our therapy and was discharged on tenth day of admission. 2. A 6-years-old girl with a chief complaint red painful eye since 2 days before admission. On admission, the eye was very inflamed with limited movement. The USG revealed vitreous haze suggestive of endophthalmitis. She was then given systemic and intravitreal antibiotics but showed poor response. Intravenous steroid was then given and the condition was improved. She was discharged on the fifth day.

Discussion: Our two patients came with two different presentations and responds to systemic antibiotics which was considered the mainstay of treatment in endogenous endophthalmitis. The first patient responded well with systemic and intracameral antibiotics while the second patient condition was improved only after the addition of intravenous steroid. Close observation with re-examination and re-evaluation should be done repeatedly to decide which treatment option should be administered.

Conclusion: Diagnosis and management of young patient with endogenous endophthalmitis is challenging. Thorough history taking, physical examination, laboratory examination, and microbiology examination should be done to make a prompt diagnosis and management.

Keywords: endogenous endophthalmitis, children, management, steroid

INTRODUCTION

ndophthalmitis is one of the most devastating diseases in ophthalmology that can lead to blindness or even loss of the eyeball. It is an inflammatory disorder of intraocular cavities caused by infecting organism from exogenous or endogenous spread.¹ Exogenous

endophthalmitis occurs from direct inoculation of infective agent from outside environment to the intraocular cavities caused by intraocular surgery and trauma. Endogenous endophthalmitis occurs secondarily from distant focus of infection through hematogenous dissemination that cross the blood- retina barrier. Liver abscess is the most reported focus of infection in endogenous endophthalmitis, followed by pneumonia, endocarditis, urinary tract infection, meningitis, and septic arthritis.^{2,3}

Endogenous endophthalmitis only accounts for about 2-8 % of all endophthalmitis cases, mostly in adult patients.⁴ Pediatric cases were only reported in 0,1-4% of all endogenous endophthalmitis, and India has the highest reported cases.⁵ It may be caused due to poor hygiene, high antibiotic resistance, and lower birthweight infant in India.⁶ Due to its rarity, endogenous endophthalmitis in pediatric patient is often not expected and misdiagnosed as uveitis, cellulitis, congenital glaucoma, conjunctivitis or retinoblastoma. This often causes delay in the diagnosis that related to poorer prognosis.^{4,7}

Maitray et al. reported in their 20 years long case series of endogenous endophthalmitis in pediatric age group (age < 18 years) that gram positive bacteria were evident in 37% cases, fungi in 10% cases and *Toxocara* in 27% cases.⁴ In Europe and North America, it is mostly caused by *Staphylococcus aureus* and *Streptococcus pneumonia* whilst in Asia it is caused primarily by *Klebsiella pneumonia*. *Candida albicans* is the most common yeast etiology and, aspergillus is the most common mold.⁸

The diagnosis of endophthalmitis is made based on clinical findings. Symptoms can vary from very mild inflammation in anterior chamber and anterior portion of vitreous to severe panophthalmitis with severe pain with no fundus view, corneal edema, or complete hypopion. Hypopion can be examined in 75% of endophthalmitis patients, whereas severe ocular pain that most ophthalmologists regard as pathognomonic sign was absent in 25% of patients. Most common presentations, independent of its sources, are decreased visual acuity, ocular pain, redness, corneal edema, and vitritis.⁸⁻¹⁰

The prognosis of endophthalmitis regardless of its origin is poor. Its seen as an ocular condition that leaves patients with very limited visual function. Therefore, early diagnosis and treatment with broad spectrum antimicrobial therapy are fundamental to optimized the outcome. Pars plana vitrectomy as a mean to reduce pathogen, toxins, inflammatory materials, and opacities shows clear benefit in exogenous endophthalmitis management.^{6,11} In contrast with exogenous endophthalmitis: in managing endogenous endophthalmitis, systemic antibiotic is the mainstay of treatment.¹² Because the source of infection is outside the eye, but within the body, blood and urine cultures must be obtained.¹³ The role of vitrectomy in endogenous

endophthalmitis is not exactly defined and considered as supplementary. One reason for this could be that data from the Endophthalmitis and Vitrectomy Study (EVS) may not be applicable because the spectrum of causative organisms differs significantly in endogenous endophthalmitis.¹⁴ Although systemic and intravitreal antibiotics may be sufficient in milder forms of infection, vitrectomy seems to be helpful in severe cases of endogenous endophthalmitis because more virulent organisms, such as endotoxin-producing *Streptococcus* and *Bacillus* species, are commonly involved.¹³

In this paper will share our experience in managing two rare cases of endogenous endophthalmitis in two very young and immunocompetent patients.

CASE ILUSTRATION

First Patient

First patient was a 2-year-old boy that came to our clinic with chief complain left eye redness for 10 days. He also complained painful eye and losing sight in his left eye. His mom said that about 2 weeks before admission, her child had contacted kid with pink eye problem. She assumed that her kid got his eye problem from that kid. His mom denied profuse purulent secretion. His mom said that there were no history of “cat eye” nor eye misalignment prior to the complaint. There is no known history ocular trauma or surgery prior to admission. The immunization history was complete.

On physical examination, there was palpebral spasm and edema, conjunctival and ciliary injection was also present. The cornea was slightly hazy and there was no staining of fluorescein. There was hypopyon and his pupil appeared leukocoric. The posterior segment examination was hard to be evaluated. USG examination showed vitreous opacities suggestive of vitritis. Visual acuity and intraocular pressure was hard to be examined because of uncooperative patient.

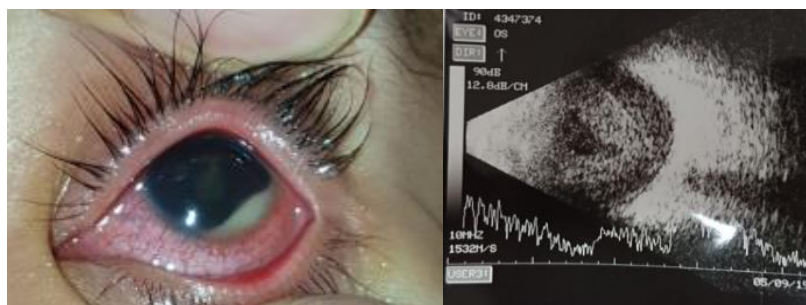


Figure 1. The left eye showed hypopyon and vitreous haze at the time of admission.

The patient was diagnosed as endogenous endophthalmitis of the left eye and treated with intravenous ampicillin-sulbactam 900 mg four times a day, levofloxacin eye drop six times a day, prednicolone acetate and atropine sulphate eye drop .We consulted this patient to Pediatric, Ear-Nose-Throat, and Dentistry Clinics for further examination on focus of infection. Blood and urine examination and culture were also done.

On third day, there was some improvement. The USG showed decreasing vitreous opacities. His blood culture result was found to be sterile. From his urine culture, we found *Candida* sp. with colony count of 5600 cells/ ml. The ENT, Dentistry, and Pediatric department did not found any focus of infection. There was leucocytosis ($14,66 \times 10^3/\text{ul}$) but normal C-reactive protein and procalcitonin value indicating local infection.

On Fourth day, there was worsening vitreous opacities found in USG. Patient was still complaining pain in his left eye. The hypopion in anterior chamber was 2 mm, then we injected intracameral vancomycin, ceftazidime, and levofloxacin, and aspirated the hypopion. We sent the aspirate for culture to clinical pathology department that later found no organism. One day after surgery, the eye condition was improving, no hypopion in anterior chamber, and the vitreous opacities was decreased. He was discharged with levofloxacin, prednisolone acetate, atropin sulphate eye drops, and amoxicillin clavulanid acid 125 mg three times daily.

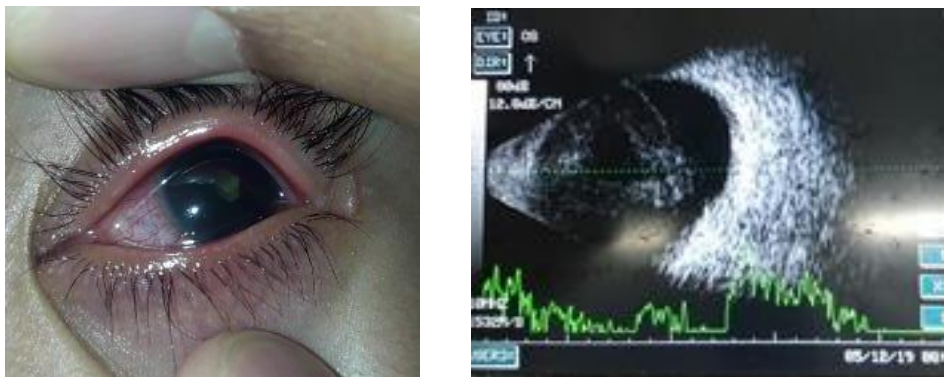


Figure 2. The left Eye inflammation and vitreous haze had improved at time of discharge

Second Patient

Second patient was a six-years-old girl with chief complain of painful and swollen right eye since two days before admission. She rubbed her eyes and the eyes became more swollen. Her parent said that her siblings got pink eye problem one weeks before admission. Her parents then brought her to nearest general practitioner and got an eye ointment and an eye drop but forgot the name, then referred to our hospital. She had history of dental problem and no history

of ear discharge, pain when urinating, sore throat, or flu like symptoms. Her parents said that their daughter immunization was complete.

At the time of admission her left eye movement to temporal, inferior and nasal site was limited. Her left eye visual acuity was hand movement with good projection and the intraocular pressure was 23 mm Hg. There was conjunctival and ciliary injections with chemosis in the nasal, inferior and temporal. The cornea was hazy with microcystic oedema. The anterior chamber was deep with cells 4+ and fibrin. The pupillary reflex was absent and the lens was covered with fibrin. The fundus was hard to be examined so USG examination was done and revealed vitreous haze.

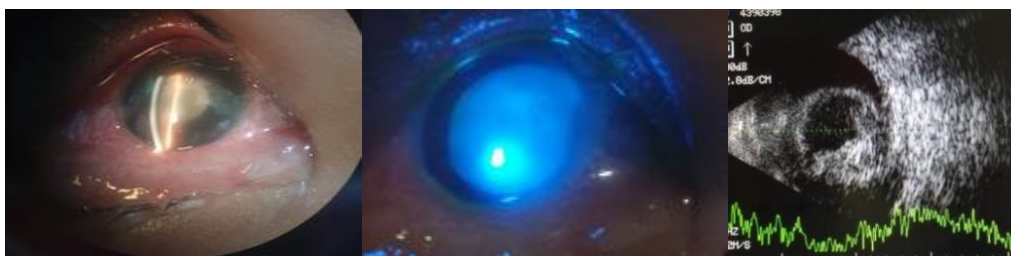


Figure 3. Physical and USG presentation of the second patient's right eye at the time of admission showed marked inflammation and vitreous haze.

She was assessed with endogenous endophthalmitis of the right eye. Blood examination revealed leucocytosis ($13.74 \times 10^3/\text{ul}$), elevated procalcitonine (0.16 ng/ MI) and elevated C-reactive protein (77.8 mg/L) indicating acute bacterial infection. We also consulted to Pediatric, ENT, and Dentistry Department for focal of infection evaluation. Intravitreal injection of vancomycin and ceftazidime was administered immediately and the vitreous was taken for culture. Later, the vitreous culture found no microorganism growth. We also give her levofloxacin eye drop per hour, sulfas atropine eye drop three times a day, ceftriaxone 1400 mg intravenously once per day, and ibuprofen syrup 100 mg three times a day.

After intravitreal injection, the eye became more inflamed and her visual acuity decreased to light perception. The intraocular pressure was increased to 33 mmHg. She continued on her medication with an added timolol 0,5% and methylprednisolone 125 mg per day intravenously.

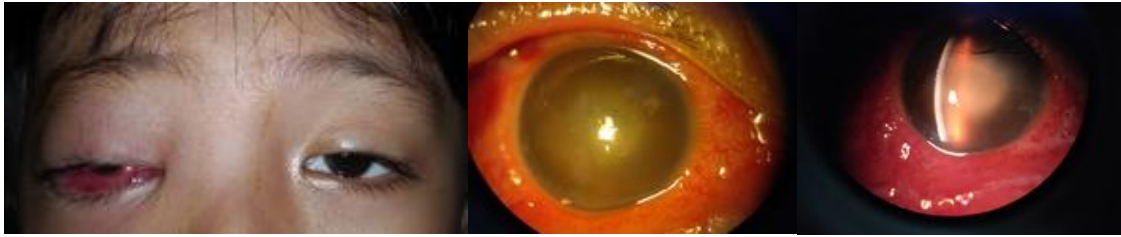

Figure 4. Eye presentation of the second patient one day after intravitreal antibiotic injection

Two days post operation, the condition was improved with reduced of inflammation and chemosis. Her condition was getting better and she was discharged on fourth day. We changed her intravenous steroid and antibiotic to oral methylprednisolone 8 mg three times a day, cefixime 150 mg two times a day, and continued other medication.

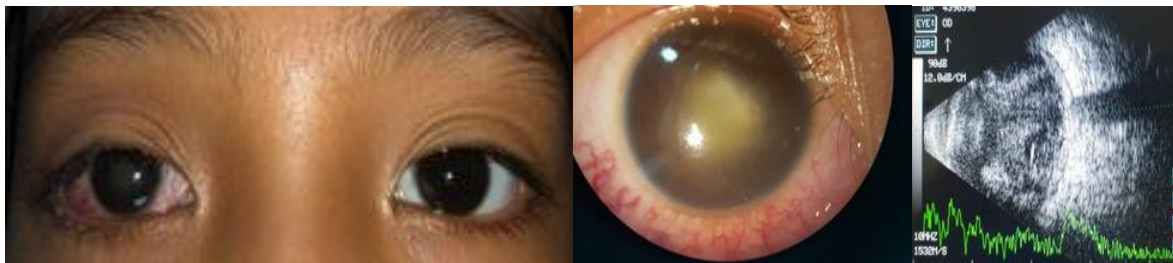


Figure 5. Eye and USG examination at the time of discharge

DISCUSSION

Endogenous endophthalmitis has a spectrum of presentations from asymptomatic to full blown hot eye with proptotic and chemotic eyes. Fungal endogenous endophthalmitis can resemble bacterial infection in its initial presentation and should always be considered in patient with immunocompromised states or with candidemia. Earliest sign of endogenous endophthalmitis such as Roth's spots (round, white retinal spots surrounded by haemorrhage) and retinal periphlebitis can be seen using funduscopy.¹⁵ We also must look for immunocompromised condition: diabetes mellitus, malignancy, sickle cell disease, HIV, end stage liver disease, or in immunomodulatory therapy for transplants and autoimmune disease. We usually can find systemic sign of infection in endogenous endophthalmitis patient: fever, elevated leucocyte count, and positive culture from other part of the body (pneumonia, urinary tract infection, bacterial meningitis, infective endocarditis, or liver abscess).³

Our patient in this report came with two different presentation of endogenous endophthalmitis. Based on these clinical findings and anamnesis we diagnosed the patients with endogenous endophthalmitis. We suspected it was caused by bacteria because the patients were not in immunocompromised state. We did not found any foci of infection even after consulting

to other department in first patient. It was stated in 18 years retrospective case series by Binder et al. that in 44% of patient, there was no additional focus of infection beside the eyes was found, suggesting the concept of transient bacteriemia or fungemia as a possible cause of endogenous endophthalmitis.¹⁶

Endogenous endophthalmitis presents challenge to determine the infecting agent, medical and surgical treatment. Additional intravitreal antibiotics administration is still controversial because there is no clear consensus regarding specific indications. The rationale for the use of intravitreal injections as an adjunct to intravenous therapy is the reduced permeability of the retinal pigmented epithelium to systemically administered drugs. Some recommend the use of intravitreal antibiotics only when the intravenous antibiotics seems to be failing (the eye presentation shows no significance difference in outcome compared to antibiotic/ antifungal alone).^{14,17,18} If the suspected organism are bacterial, treat the patient with broad spectrum intravenous antibiotic covering both gram positive and negative, such as combination of vancomycin and an aminoglycoside or third generation cephalosporin. For fungal etiologies we can administered intravenously antifungals: amphotericin B (AMB), voriconazole, or fluconazole.^{9,10}

In our first patient, we only gave intravenous ampicillin sulbactam with no intravitreal antibiotic injection because the eye was not hot in appearance. We observed the patient condition for antibiotic response for 48 hours. Because the eye responded well to intravenous ampicillin-sulbactam treatment (the pain and inflammation was reduced), we continue the therapy without any addition of antifungal. We also did an aspiration of hypopion in anterior chamber with intracameral antibiotics afterwards to remove infective material.

For our second patient, we gave ceftriaxone intravenously combined with intravitreal vancomycin and ceftazidime injections because the eye was very hot in appearance. The eye inflammation was getting worse and her visual acuity was decreased to no light perception two days after intravitreal injection. We gave her intravenous steroid with methylprednisolone 125 mg once per day to reduce the inflammation and it responded well to steroid therapy. The role of corticosteroid in endogenous endophthalmitis management is still controversial. There is no clear guideline for the use of intravitreal or systemic corticosteroid as many research shows conflicting results.² Inflammation that is essentials for fighting the infecting organism, may also end up damaging ocular structures. A prospective multicenter randomized placebo-control trial of intravitreal dexamethasone as adjuvant therapy for endophthalmitis reported no significance safety risk of corticosteroid.¹⁹ Jackson et al., also stated in their systematic review that intravitreal dexamethasone was associated with better final visual acuity and lesser

evisceration/enucleation.²⁰ On the contrary, Shah et al. reported a found a reduced likelihood of obtaining improvement in visual outcomes following the use of intravitreal steroids.²¹ Because of limited and conflicting data we recommends close observation regarding the use of steroids .

We did not do pars plana vitrectomy in both of our patients due to unfortunate settings. The decision of doing vitrectomy is usually based on clinical judgement as there is no consensus about the specific indication for endogenous endophthalmitis.¹¹ Maitray et al., recommend early vitrectomy and intravitreal antibiotics in addition to systemic antibiotic.⁴

We managed to save both patients from losing their eyeball, but didn't manage to save their visual function. We told the parents that their children visual prognosis was not good and will become pthysical in the future. It was reported in Lu et al., study that evisceration/enucleation rate can reach 41% of endogenous endophthalmitis cases.

CONCLUSION

Endogenous endophthalmitis in young and healthy patient is very rare but devastating disease that have very poor prognosis. It is often unexpected and misdiagnosed because its rarity. High degree of suspicion and thorough examination is required to make accurate diagnosis and treatment.

Ideal treatment for endogenous endophthalmitis is still controversial as researches showed conflicting results. Intravenous antibiotics is considered mainstay of treatment. The need for intravitreal antibiotics and vitrectomy is controversial as there is no consensus about the specific indications. Corticosteroid use in managing inflammation in endogenous endophthalmitis is also controversial therefore judicious and tailored corticosteroid use is warranted.

REFERENCES

1. Durand ML. Endophthalmitis. *Clin Microbiol Infect.* 2013 Mar 1;19(3):227–34.
2. Sadiq MA, Hassan M, Agarwal A, Sarwar S, Toufeeq S, Soliman MK, et al. Endogenous endophthalmitis: diagnosis, management, and prognosis. *J Ophthalmic Inflamm Infect.* 2015 Dec;5(1):32.
3. Birnbaum F, Gupta G. Endogenous Endophthalmitis: Diagnosis and Treatment. *EyeNet Mag.* 2016;June:33–5.
4. Aditya Maitray, Ekta Rishi, Pukhraj Rishi, Lingam Gopal, Pramod Bhende, Rupak Ray KLT. Endogenous endophthalmitis in children and adolescents: Case series and literature review. *Indian J Ophthalmol.* 2019;
5. Okada AA, Johnson RP, Liles WC, D'Amico DJ, Sullivan Baker A. Endogenous Bacterial Endophthalmitis: Report of a Ten-year Retrospective Study. *Ophthalmology.* 1994 May 1;101(5):832–8.
6. Basu S, Kumar A, Kapoor K, Bagri NK, Chandra A. Neonatal endogenous endophthalmitis: A report of six cases. *Pediatrics.* 2013;131(4).
7. Larson KE, Carrillo-Marquez M. Endogenous methicillin-resistant *Staphylococcus aureus* endophthalmitis after leg trauma. *J AAPOS.* 2015;19(4):387–9.

8. Dave VP. Clinical presentations, microbiology and management outcomes of culture-proven endogenous endophthalmitis in India. *Indian J Ophthalmol*. 2020;
9. Cho H, Shin YU, Siegel NH, Yu HG, Sobrin L, Patel A, et al. Endogenous Endophthalmitis in the American and Korean Population: An 8-year Retrospective Study. *Ocul Immunol Inflamm*. 2018;26(4):496–503.
10. Durand ML. Endophthalmitis. *Clin Microbiol Infect*. 2013;19(3):227–34.
11. Danielescu C, Anton N, Stanca HT, Munteanu M. Endogenous Endophthalmitis: A Review of Case Series Published between 2011 and 2020. *J Ophthalmol*. 2020;2020.
12. Lim SW, Sung Y, Kwon HJ, Song WK. Endogenous Endophthalmitis Associated with Liver Abscess Successfully Treated with Vitrectomy and Intravitreal Empirical Antibiotics Injections. *Case Rep Ophthalmol Med*. 2020;2020(Figure 1):1–4.
13. Dave VP. Clinical presentations, microbiology and management outcomes of culture-proven endogenous endophthalmitis in India. *Indian J Ophthalmol*. 2020;
14. Results of the Endophthalmitis Vitrectomy Study. A randomized trial of immediate vitrectomy and of intravenous antibiotics for the treatment of postoperative bacterial endophthalmitis. Endophthalmitis Vitrectomy Study Group. *Arch Ophthalmol (Chicago, Ill 1960)*. 1995 Dec;113(12):1479–96.
15. Kumar R, Bansal V, Halder V, Chakraborty NS, Gourav KP. An unusual case report of mitral valve apparatus sparing left atrial appendage vegetation presenting as endogenous endophthalmitis. *Egypt Hear J*. 2021;73(1).
16. Binder, Monica I. MD; Chua, Jimmy MD; Kaiser, Peter K. MD; Procop, Gary W. MD; Isada CMM. Endogenous Endophthalmitis An 18-Year Review of Culture-Positive Cases at a Tertiary Care Center. *Medicine (Baltimore)*. 2003;
17. Essman TF, Flynn HW, Smiddy WE, Brod RD, Murray TG, Davis JL, et al. Treatment outcomes in a 10-year study of endogenous fungal endophthalmitis. *Ophthalmic Surg Lasers*. 1997 Mar;28(3):185–94.
18. Chung KS, Kim YK, Song YG, Kim CO, Han SH, Chin BS, et al. Clinical review of endogenous endophthalmitis in Korea: a 14-year review of culture positive cases of two large hospitals. *Yonsei Med J*. 2011 Jul;52(4):630–4.
19. Lindstedt, E.W.; Bennebroek, C.A.; Werf, D.J. van der; Veckeneer, M.; Ossewaarde-van Norel, A.; Nielsen, C.C.M.; Wubbels, R.J.; Dissel, J.T. van; Meurs JC van. A prospective multicenter randomized placebo-controlled trial of dexamethasone as an adjuvant in the treatment of postoperative bacterial endophthalmitis: interim safety analysis of the study drug and analysis of overall treatment results. *Pubmed*. 2014;
20. Jackson TL, Paraskevopoulos T, Georgalas I. Systematic review of 342 cases of endogenous bacterial endophthalmitis. *Surv Ophthalmol*. 2014;59(6):627–35.
21. Shah GK, Stein JD, Sharma S, Sivalingam A, Benson WE, Regillo CD, et al. Visual outcomes following the use of intravitreal steroids in the treatment of postoperative endophthalmitis. *Ophthalmology*. 2000;107(3):486–9.
22. Johnson TM. Endophthalmitis Vitrectomy Study. *Can J Ophthalmol*. 2003;38(4):264.