

ORIGINAL ARTICLE

VARIATION OF THE AXIAL LOCATION OF BRUCH'S MEMBRANE OPENING, GANGLION CELL INNER PLEXIFORM LAYER AND FLUX INDEX IN NORMAL TENSION GLAUCOMA AND PRIMARY OPEN ANGLE GLAUCOMA PATIENTS

Jehan Fauzi Rakhmandani¹, Retno Ekantini¹, Tatang Talka Gani¹, Krisna Dwi Purnomo Jati¹

¹Department of Ophthalmology, Faculty of Medicine, Public Health, and Nursing, Universitas Gadjah Mada, Dr. Sardjito General Hospital, Yogyakarta, Indonesia
Email: rakhmandanijehan@gmail.com

ABSTRACT

Introductio: Bruch's membrane opening (BMO) at the most anterior point of the neural canal for quantification of cup depth /based on retinal surface position, area and volume, laminar position, and prelaminar connective tissue volume. If these deep structural parameters are to be used effectively in glaucoma detection and identification of progression.

Purpose: This study explores variation in the axial location of Bruch's membrane opening (BMO) to determine if this reference plane varies with NTG and POAG patients.

Methods: This was a cross-sectional prospective descriptive study with purposive sampling. This study enrolled 72 eyes in Sardjito General Hospital underwent cirrus – OCT 5000 Ver 11.0.0.29946 between 1st March 2022 and 10th May 2022.

Results: We evaluated 72 (25 NTG and 47 POAG) eyes on 37 outpatients service of Sardjito General Hospital. Median BMO, GCIPL, Flux index and CD ratio of NTG patients was 1.707 μm (1.387-2.182), 83,0 μm (76-88), 0,40 (0,27-0,48), 0,64 (0,22-0,75). Median BMO, GCIPL, Flux index and CD ratio of POAG patients was 1.612 (1.028-2.031) μm , 79,00 (56-98) μm , 0,40 (0,26-0,47) and 0,64 (0,28-0,92) for CDR. Bruch's membrane opening position was more posterior relative to the sclera in older subjects with negative correlation (P value = 0,07). Variable BMO and GCIPL tested between NTG and POAG group showed significant difference with BMO P value = 0,04 and GCIPL P value=0,01 except Perfusion, flux index and RNFL.

Conclusion: Bruch's membrane opening is more posteriorly located in older individuals. There was significant difference p value of BMO between the mean of NTG and POAG.

Keyword : Bruch's membrane opening (BMO), Normal Tension Glaucoma, Primary Open Angle Glaucoma

INTRODUCTION

Glaucoma is an irreversible, progressive optic neuropathy that causes nerve fiber damage, visual loss, and even blindness¹ Early detection and treatment can slow the progression of the disease; thus, identification of the structural changes in early glaucoma, such as cup-to-disc ratio and retinal nerve fiber layer (RNFL) thickness, is important².

Total of 2.78% of visual impairment in the world is caused by glaucoma. In the case of blindness, glaucoma is the second leading cause, after cataracts, in the world. Glaucoma generally has no obvious symptoms. If not treated immediately, glaucoma will cause irreversible vision loss which can lead to blindness. In Indonesia, according to Riskesdas in 2007, the prevalence of glaucoma was 0.46%, meaning that 4 to 5 people out of 1,000

Indonesians suffer from glaucoma. Based on online hospital application data, the number of glaucoma visits in outpatients in hospitals during 2015-2017 has increased.³ Bruchs membrane opening (BMO) or neural canal opening, which remains stable with the progression of glaucoma, is an important biomarker in the optic nerve head (ONH) in Spectral-Domain Optical Coherence Tomography (SD-OCT). It is defined as the termination of the retinal pigment epithelium (RPE) layer. As introduced in, the BMO points in SD-OCT represent the true position of the optic disc. Thus, the disc margin can also be identified by aligning the color fundus image and the SD-OCT volumes.⁴

Histologically, the optic nerve head (ONH) is a three-layered opening through which the axons of the retinal ganglion cells (RGCs) pass; the innermost layer is Bruch's membrane opening (BMO), the middle layer is the choroidal opening, and the third layer is the scleral canal opening⁵. Among the three openings, BMO is a clearly identifiable anatomical structure on spectral-domain optical coherence tomography (SD-OCT) and is thought to remain stable over time; thus, BMO is considered an anatomically more accurate and reliable landmark than is the conventional clinical disc margin when evaluating glaucoma⁶. Recently, BMO-based minimum rim width (MRW) measurement has become a new standard for documenting neuroretinal rim dimensions. Previous studies have reported that it has higher diagnostic accuracy for glaucoma and stronger relationship with visual field (VF) damage than do the conventional rim parameters⁷. There are conflicting results on the association between BMO area and myopia. Some studies reported a positive correlation between BMO area and axial length. In contrast, a study on a normal Caucasian population reported that BMO area was not significantly associated with axial length⁸. Moreover, in a recent prospective and longitudinal observational study, Kim *et al*⁹ showed that the distance between two BMO points on horizontal OCT B-scan images remained stable during myopia progression. Recently in independent studies, BMO-MRW has been reported to have higher correlation with visual field damage and higher diagnostic accuracy for glaucoma than conventional disc margin-based neuroretinal rim parameters.¹⁰ It has also been proposed that OCT data acquisition and analyses be performed according to the individual eye-specific axis between the fovea and BMO center (FoBMO axis) to standardize image acquisition such that normative databases can be more accurate.¹¹

METHODS

Patient and Data Collection

This cross-sectional study involved from patients diagnosed with NTG (Normal Tension Glaucoma) and POAG (Primary Open Angle Glaucoma) using consecutive sampling. This study enrolled outpatients service of Sardjito General Hospital who underwent cirrus – OCT 5000 Ver 11.0.0.29946 examination between 1st march 2021 until 10th May 2022. Patients' data presenting sex, age, visual acuity, Spherical equivalent and diagnosis. We used OCT Angiography tool. Patients with inclusion criteria with NTG and POAG, tool part in the research and sign the research consent form and OCT-A of ONH results with signal strength over 8 were performed. Exclusion criteria were patients who refused to participate in the study and media opacity that alter the quality of imaging, and previous intraocular surgical procedures other cataract surgery. Patients who have agreed to be examined are then subjected to long-distance and near-distance visual examinations with digital snellen chart then corrected with spectacles. After that, the patient was given mydriatic drops for right and left eye to OCT examination.

Statistycal Analysis

The sample size of the study was calculated using the SPSS program. In the power analysis performed of median impact size and mean size, 72 eyes were appropriate. All data obtained from the participants have expressed as the mean \pm standard deviations (SDs). Comparison of BMO, RNFL, GCIPL, Perfusion and Flux Index between NTG groups and POAG group compared using Mann-Whitney U test. Comparison of Spherical equivalent between NTG groups and POAG group using T-test. Correlations between variables BMO and age were determined using Pearson's correlation tests.

RESULTS

We evaluated 72 eyes from 37 patients, consisted of 25 eyes (34%) NTG and 47 eyes (65%) POAG. The mean of the subject subjects were 44,39 years old from 72 eyes, consisted of 36(50%) female and 36(50%) male. Number of male on NTG were 10 eyes and 26 eyes on POAG also 15 female NTG and 21 on POAG.

Median BMO, GCIPL, Flux index and CD ratio of NTG patients was 1.707 μm (1.387-2.182), 83,0 μm (76-88), 0,40 (0.27-0,48), 0,64 (0,22-0,75). Median BMO, GCIPL, Flux index and CD ratio of POAG patients was 1.612 (1.028-2.031) μm , 79,00 (56-98) μm , 0,40 (0,26-0,47) and 0,64 (0,28-0,92) for CDR. Figure 2 shows the result ,Bruch's membrane opening position was more posterior relative to the sclera in older subjects with negative correlation (P value = 0,07).

Table 2 shows the results of mean of OCTA BMO were 1.713 NTG and 1.596 POAG. Mean OCT ONH GCIPL were 81,4 NTG and 73,40 POAG. The table that showed multivariable mean of BMO and GCIPL tested between NTG and POAG group showed significant difference p value =0,04 of BMO and GCIPL p value=0,01 except perfusion, flux index and RNFL. Comparison of spherical equivalent between NTG groups and POAG group using T-test and showed no significant difference.

Table 1. Baseline Demographic Information

Variable	NTG N=25 eyes	POAG N=47 eyes
Age, Mean (SD) (95% CI),y	40,15 (12,67)	48,63 (14,48)
Age ≤35 y	31	30
Age 36 s/d 50 y	43,2	45,14
≥50 y	61,5	60.9
No. Of Male/Female	10 / (15)	26 / (21)
SEQ (spherical equivalent), Mean	"-1,87 (1,74)	"-1,3 (1,32)

DISCUSSION

This study demonstrated a significant association between age of BMO, with BMO located more posteriorly in older individuals. This more posterior BMO position was also associated with an observed thinning of the choroid that occurred with aging. This implies that as the with increasing age, BMO position shifts more posteriorly. This finding has important ramifications for the quantification of deep optic nerve structure since measurements of laminar and prelaminar tissue positions are based on a BMO-based reference plane. To the best of our knowledge, this is the first study examining the association of the BMO reference plane as defined by SDOCT with age.¹²

The BMO-based measurements have been used with SDOCT and with morphometric quantification of histologic reconstructions. Further work using a scleral based reference plane will be important to explore these differences both for cross-sectional detection studies and longitudinal progression studies. The structural parameters most commonly investigated are the RNFL thickness, usually assessed by OCT, and ONH parameters, commonly measured by CSLO (Slow scan mode for simultaneous). A few years ago, OCT technology improved tremendously, and all structural parameters of interest can be measured in high resolution with a single device.¹³

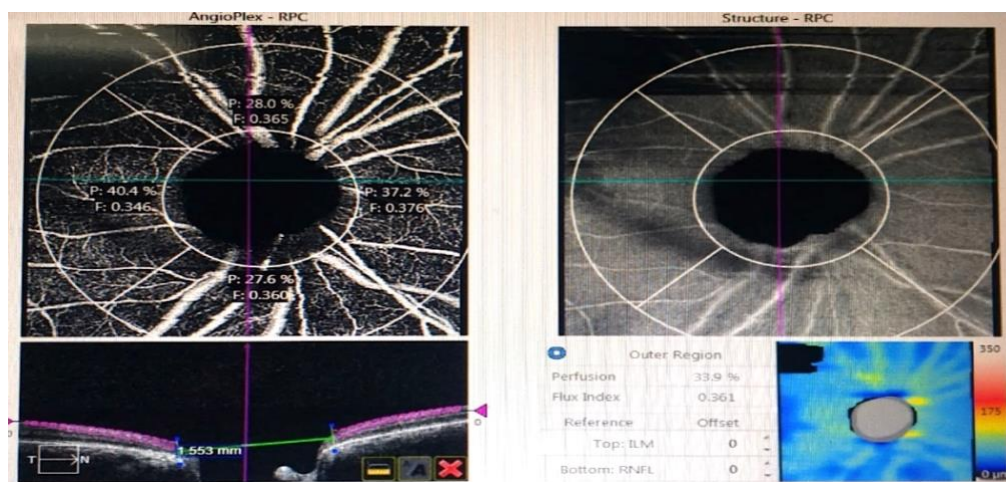


Figure 1. Representative radial section from a compensated SDOCT of the optic nerve head showing the location of placement of the scleral reference plane based on the average position of the scleral. Only Bruch's membrane surface (green lines and marks). The region of measurement of BMO located 1,553 mm.

Table 2. Comparison of BMO, RNFL, GCIPL, Perfusion and Flux Index between NTG groups and POAG group using Mann-Whitney U test

	NTG		Median	POAG		P-value
	Median	Mean (SD)		Mean (SD)		
BMO	1.707	1.713(0.22)	1.612	1.596(0,20)	0.042	
RNFL	101.00	99.68(14,20)	94.00	90.61 (19,60)	0.072	
GCIPL	83.00	81.40(9,07)	79.00	74.53(16,43)	0.01	
Perfusion	0.452	0.45(0,01)	0.45	0,44(0,03)	0.25	
Flux	0.45	0,42(0,05)	0.41	0,39(0,05)	0.19	
CDR	0,64	0,58 (0,15)	0,64	0,62 (0,14)	0.50	
Spherical Equivalent	1,00	1,20(0,76)	1,00	0,80(0,71)	0.22	

Our study has several limitations small sample size measurements taken from NTG eyes may lead to discrepancies among the studies. On this study, small variabel and uneven sample between types of NTG and POAG. Measurement at BMO height on OCT is also done manually so that each person who does it can give different results.

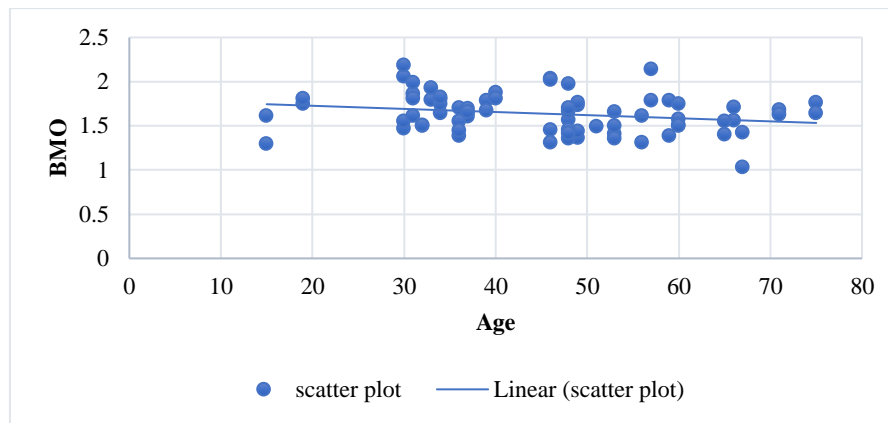


Figure 2. Scatterplot and regression line BMO height and age with negative correlation. The correlation coefficient is 0,21.

CONCLUSION

Bruch's membrane opening is more posteriorly located in older individuals. There was significant difference of BMO ($p=0,01$) and GCIPL ($p=0,04$) between the mean of NTG and POAG. OCT is a noninvasive method that can be used to assess the vascularity and structure of ONH, which is believed to be useful for diagnose and predicting prognosis in glaucoma patients.

REFERENCES

- Weinreb R. N., Khaw P. T., "Primary open-angle glaucoma," *The Lancet* 363, 1711–1720 (2004). 10.1016/S0140-6736(04)16257-0
- Yousefi S., Goldbaum M. H., Balasubramanian M., Jung T., Weinreb R. N., Medeiros F. A., Zangwill L. M., Liebmann J. M., Girkin C. A., Bowd C., "Glaucoma progression detection using structural retinal nerve fiber layer measurements and functional visual field points," *IEEE Transactions on Biomed. Eng.* 61, 1143–1154 (2014). 10.1109/TBME.2013.2295605
- Pusdatin Kemenkes. 2019. Situasi Glaukoma di Indonesia. <https://pusdatin.kemkes.go.id/article/view/19080500002/situasi-glaukoma-di-indonesia.html>
- Mwanza J.-C., Chang R. T., Budenz D. L., Durbin M. K., Gendy M. G., Shi W., Feuer W. J., "Reproducibility of peripapillary retinal nerve fiber layer thickness and optic nerve head parameters measured with cirrus hd-oct in glaucomatous eyes," *Investig. Ophthalmol. & Vis. Sci.* 51, 5724 (2010). 10.1167/iovs.10-5222
- Manassakorn A., Nouri-Mahdavi K., Caprioli J., "Comparison of retinal nerve fiber layer thickness and optic disk algorithms with optical coherence tomography to detect glaucoma," *Am. J. Ophthalmol.* 141, 105–115.el (2006). 10.1016/j.ajo.2005.08.023
- Belghith A., Bowd C., Medeiros F. A., Hammel N., Yang Z., Weinreb R. N., Zangwill L. M., "Does the location of bruch's membrane opening change over time? longitudinal analysis using san diego automated layer segmentation algorithm (salsa)," *Investig. Ophthalmol. & Vis. Sci.* 57, 675 (2016). 10.1167/iovs.15
- Strouthidis, N. G., Yang, H., Downs, J. C. & Burgoyne, C. F. Comparison of clinical and three-dimensional histomorphometric optic disc margin anatomy. *Invest Ophthalmol Vis Sci.* 50, 2165–2174 (2009).
- Jonas, J. B. & Xu, L. Histological changes of high axial myopia. *Eye (Lond).* 28, 113–117 (2014)
- Jonas, J. B., Holbach, L. & Panda-Jonas, S. Peripapillary ring: histology and correlations. *Acta Ophthalmol.* 92, e273–e279 (2014).
- Chauhan, B. C. & Burgoyne, C. F. From clinical examination of the optic disc to clinical assessment of the optic nerve head: a paradigm change. *Am J Ophthalmol.* 156, 218–227 (2013).

11. Kim, M., Choung, H. K., Lee, K. M., Oh, S. & Kim, S. H. Longitudinal changes of optic nerve head and peripapillary structure during childhood myopia progression on OCT: Boramae Myopia Cohort Study report 1. *Ophthalmology*. 125, 1215–1223 (2018).
12. Chauhan BC, Burgoyne CF. From clinical examination of the optic disc to clinical assessment of the optic nerve head: a paradigm change. *Am J Ophthalmol*. 2013; 156: 218-227.
13. Reus NJ, Lemij HG. Relationships between standard automated perimetry HRT confocal scanning laser ophthalmoscopy, and GDx VCC scanning laser polarimetry. *Invest Ophthalmol Vis Sci*. 2005; 46: 4182–4188.
14. Medeiros FA, Alencar LM, Zangwill LM, Bowd C, Sample PA, Weinreb RN. Prediction of functional loss in glaucoma from progressive optic disc damage. *Arch Ophthalmol*. 2009; 127: 1250–1256.
15. Reus NJ, Lemij HG. The relationship between standard automated perimetry and GDx VCC measurements. *Invest Ophthalmol Vis Sci*. 2004; 45: 840–84.