

## CASE REPORT

**AN ACTIVE, SIGHT-THREATENING GRAVES' ORBITOPATHY:  
A CHALLENGING CASE REPORT**

Muhammad Fariz<sup>1</sup>, Ismi Zuhria<sup>2</sup>, Susy Fatmariyanti<sup>2</sup>, Hendrian Dwikoloso Soebago<sup>2</sup>, Delfitri Lutfi<sup>2</sup>

<sup>1</sup> Resident of Ophthalmology, Dr. Soetomo General Academic Hospital

<sup>2</sup>Ophthalmologist, Ophthalmology Department, Dr. Soetomo General Academic Hospital

Email: m.fariz.razi@gmail.com

**ABSTRACT**

**Introduction:** Graves' Orbitopathy is a self-limiting autoimmune process associated with dysthyroid states, and if left untreated can lead to a number of complications, ranging from mild to sight-threatening. Corneal ulcer is one of the sight-threatening complications of Graves' Orbitopathy.

**Case Report:** A 22-year-old woman came with a complaint of blurred vision and retrobulbar pain on both eyes that happened gradually for 2 months, preceded by protrusion on both eyes. She had history of untreated hyperthyroid disease for 7 years. Her visual acuity was 1/60 and hand movement on the right and left eye, respectively. Anterior segment examination on both eyes revealed eyelids redness and swelling, redness and chemosis of conjunctiva, and corneal ulcer with descemetocoele on her right eye. All of these clinical findings support the diagnosis of an active, sight-threatening Graves' Orbitopathy.

**Discussion:** The management of this patient involves; 1) thyroid function control due to the high level of thyroid function, 2) active, sight-threatening Graves' orbitopathy management using high doses of intravenous methylprednisolon as guided by the 2016 European Group on Graves' Orbitopathy (EUGOGO) guidelines protocol, 3) Application of amniotic membrane transplant to prevent the prolapse of intraocular tissue.

**Conclusion:** By following EUGOGO guideline protocol, the clinical condition of this patient improved, but the management of an active, sight-threatening Graves' Orbitopathy remains challenging and should be covered by multidisciplinary approach.

**Keywords:** Graves' orbitopathy, hyperthyroid, descemetocoele

**INTRODUCTION**

**G**raeves' orbitopathy (GO), also called thyroid eye disease or thyroid-associated orbitopathy, is an autoimmune disorder of the retrobulbar tissue, in which Graves' hyperthyroidism (Graves' disease) is the most frequently associated with. However, it can also occur in hypothyroid state, such as in Hashimoto patients or even cases with lack of thyroid dysfunction. Ophthalmic manifestations are present in approximately up to 50 per cent of Graves' hyperthyroidism cases. <sup>1,2</sup>

Ophthalmic manifestations can vary from mild to sight-threatening. Dull, deep orbital pain or discomfort is the most common ocular manifestations, followed by unilateral or bilateral

lid lag with downgaze and upper eyelid retraction. Other presenting symptoms include symptomatic dysthyroid optic neuropathy, diplopia, lacrimation or photophobia, and blurred vision. Recent studies show that sight-threatening Graves' orbitopathy manifestations such as compressive optic neuropathy and corneal ulcer occurs only 3-5% of GO cases.<sup>3,4</sup>

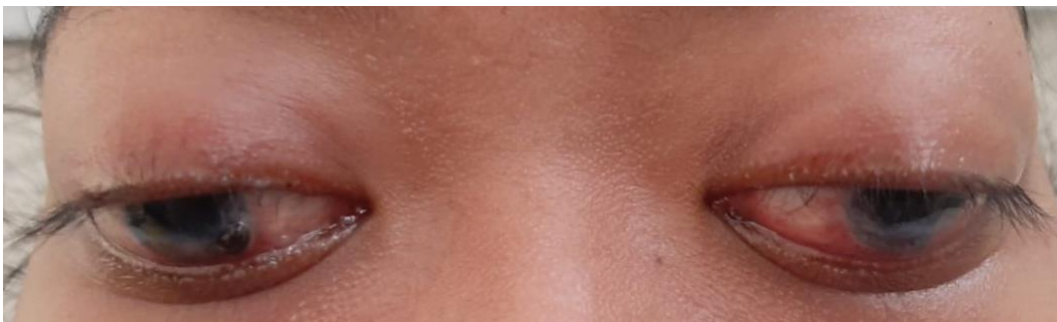Although there are no golden standards for Graves' Orbitopathy treatment as of yet, The 2016 EUGOGO guidelines recommends intravenous high-dose glucocorticoids as the first line of treatment for moderate-to-severe and active Graves' Orbitopathy. Shared decision-making is recommended for selecting second-line treatments, including a second course of intravenous glucocorticoids, and combination of oral glucocorticoids.<sup>5</sup>

This case report will present the clinical manifestations, and the challenging, multidisciplinary approach management of an active and sight-threatening Graves' orbitopathy in a 22-year old woman.

## CASE ILLUSTRATION

A 22-year-old woman came to Ophthalmology outpatient clinic with a complaint of blurred vision and retroorbital pain on both eyes that happened gradually in 2 months. Patient had trouble moving her eyeballs to all the directions and felt pain when she attempted to. Patient also complained about whitish appearance on the bottom part of both eyes since 2 months, followed by excessive tearing and redness.

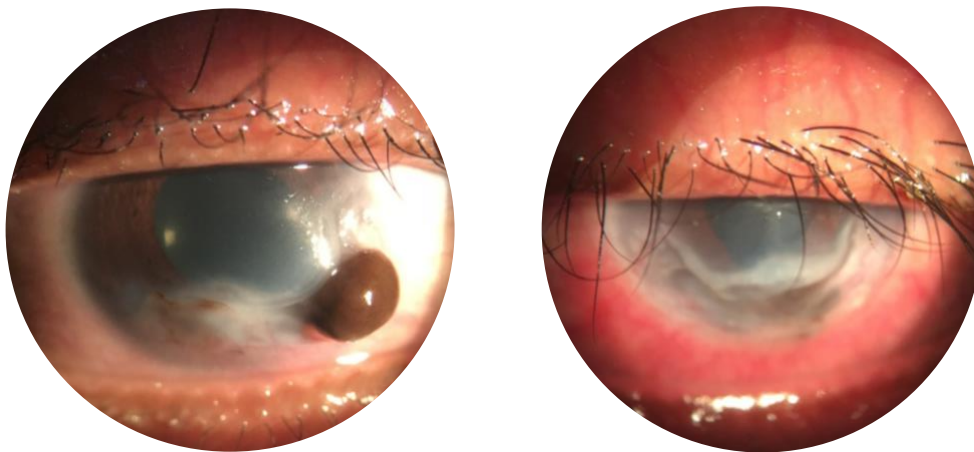
She had a history of thyroid disease for 9 years, and had undergone therapy in Endocrine division of Pediatric Outpatient clinic for only 2 years, but was left without treatment for the rest 7 years due to her family's economic condition. She felt that her eyes were protruding since 9 years ago, but worsened for the last 2 months. There were also swelling and redness of her eyelid of both of her eyes.



**Figure 1.** Macro appearance of anterior segment of both eyes

On general physical examination, we found the patient had a blood pressure of 110/80 mmHg, heart rate 80x/minute, regular heartbeat, and 16 times per minute of respiratory rate.

On ophthalmological examination, the best corrected visual acuity (BCVA) was 1/60 on her right eye and hand movement on her left eye. The anterior segment examination of both eyes showed eyelid redness and swelling, redness of conjunctiva, without any swelling of caruncle and no chemosis. We found stromal-depth infiltrate on the inferior part of both corneas measured up to 2 mm x 5 mm and 1 x 3 mm in size on her right eye and left eye respectively. We conducted a fluorescein test which showed positive results with the same size on both eyes. We also found a descemetocoele on her right eye.



A

B

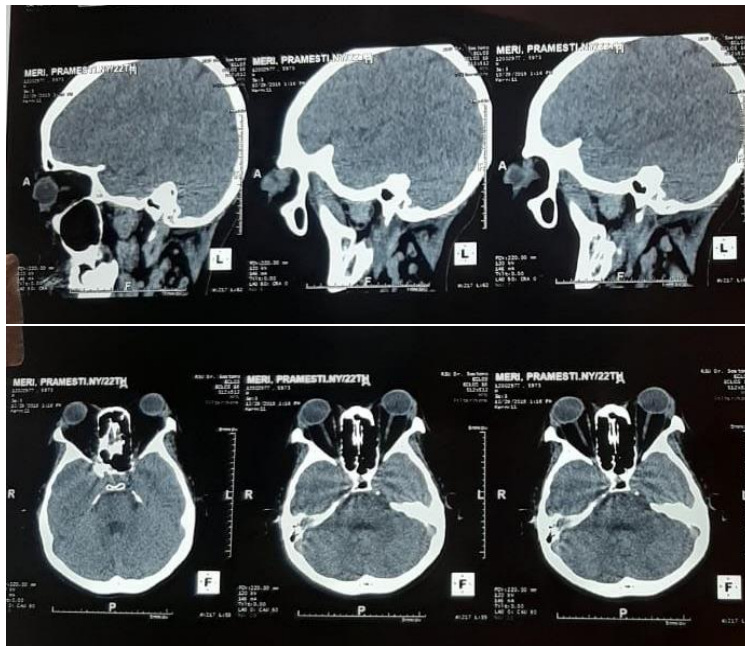
**Figure 2.** Slit-lamp examination of patient's right eye (A) and left eye (B). Patient was not cooperative while opening her eyes due to pain when her eyes were touched

Extraocular eye movements showed limitation in all directions.. The pupillary reactions were difficult to be evaluated. Intraocular pressure was normal palpation both eyes. Fundus examinations was hard to evaluate because of the swelling of the eyelids and the position of corneal ulcers.

Hertel exophthalmometer examination showed the distance between lateral orbital rim to the cornea were 23 mm and 25 mm on right and left eye respectively, and 112 cm distance between lateral orbital rim of both eyes. protrusion on both eyes. Color vision testing were 11/14 on the right eye and difficult to evaluate on the left eye.

On blood tests, including complete blood count (CBC), Liver Function Tests, Renal Function Tests, lipid profile, blood sugar profile were in normal limits. Thyroid function test found abnormalites on FT4 with 2,39 score (normal value is within 0,89-1,86) and 0,002 score on TSH (normal value within 0,55-4,78).

Computed-tomography (CT-Scan) with contrast was performed and showed lesion with protrusion component of right bulbus oculi so far as 2,4 cm and 2,7 cm on left bulbus oculi from interzygomatic line. (Figure 5).



**Figure 3.** CT-Scan imaging revealed showed lesion with protrusion component of right and left bulbous oculi

A diagnosis of right left eye thyroid-associated orbitopathy, and right left eye corneal ulcer with right eye descemetocoele were made after overseeing the clinical manifestations, and also the laboratory and imaging examinations.

Patient was admitted to the inpatient ward and was treated with Metilprednisolon 250 mg injection every 6 hours for 3 days, Atropine eye drop every 12 hours on both eyes, Levofloxacin eye drop every 2 hours on both eyes, Artificial tears eyedrop every 2 hours on both eyes, Doxicyclin 100 mg every 12 hours orally and Chlorampenicol eye ointment every night on both eyes. Patient then was consulted to the Infection and Immunology Department and then was performed an amniotic membrane transplant on her right eye with local anesthesia.

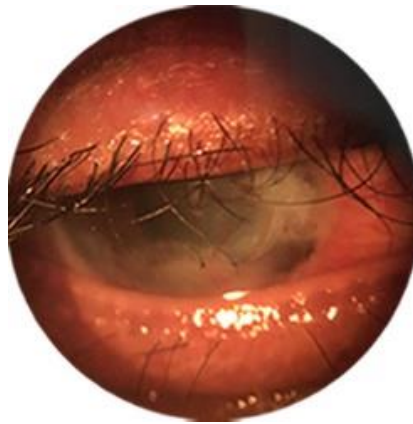This patient was also consulted to the Internal Medicine department and was diagnosed with Hyperthyroid without Thyroid Crisis (Grave's Disease) and was prescribed with Thyrozol 10 mg once a day, and Propanolol 10 mg every 12 hours orally.

After the first initial dose of methylprednisolone, we saw that the condition of the patient was improved; the eyelids redness and swelling lessen and the conjunctival hyperemia decreased. The visual acuity was also improved, though not really significant. Due to a great response to the therapy, we then planned to proceed to the maintenance dosage for the methyprednisolone into 0.5 g once weekly for 6 weeks.



**Figure 4.** Anterior segment of patient's eyes after 6 weeks of high dose intravenous methylprednisolon injection

The amniotic membrane transplant graft procedure on the patient's right eye produced a good result, with an intact AMT after a few days, it also helped preventing the prolapse of the cornea while patient underwent the methylprednisolone injection. Orbital wall decompression will be planned after the thyroid function is stable.



**Figure 5.** Patient's right eye after the application of AMT

## DISCUSSION

Graves' orbitopathy (GO), is an autoimmune disorder of the retrobulbar tissue, which most commonly occurs in individuals with Graves' hyperthyroidism, although it may also occur with Hashimoto thyroiditis (immune- induced hypothyroidism) or in the absence of thyroid dysfunction. Graves' orbitopathy may precede or follow endocrine manifestations but they tend to present within 18 months of each other in 80 per cent of patients. Graves' orbitopathy and Graves' hyperthyroidism can occur at any age but the more frequently affected are women in their third to fifth decade of life.<sup>1,2</sup>

In this patient, we found some clinical manifestations that lead to an active state of Graves' orbitopathy. Signs and symptoms such as retrobulbar pain, pain on eye movement, redness and swelling of eyelids, conjunctival hyperemia were found on this patient. The patient also shows upper eyelid retraction on both eyes, which also was found in almost 90% GO patients. Our diagnosis was confirmed with the laboratory result, as we found high T4 level and

low TSH level and radiology examination.

There are a few classifications used for Graves' orbitopathy based on the severity of cases, including Werner's 'NO SPECS' mnemonic and VISA (Vision, Inflammation, Strabismus, Appearance) classification and The European Group on Graves' Orbitopathy (EUGOGO) Clinical Activity Score (CAS).<sup>2,5</sup>

Based on the activity assessment according to Clinical Activity Score, an active state was valued at the score of  $\geq 3$ , while this patient was valued at 5 at the time of the examination.<sup>2,5</sup>

According to EUGOGO the presence of dysthyroid optic neuropathy and/or corneal breakdown can be classified as a sight-threatening GO. Due to the difficulty of examining this patient's posterior segment, we could not determine whether DON had already been appeared on this patient. The blurred vision might be caused by DON or the corneal ulcer we found. With the appearance of corneal ulcer with descemetocoele we can classify this patient of having the sight-threatening complications of GO.<sup>5</sup>

Based on a few studies, corneal ulcer as a manifestation of GO is rare, occurs in less than 2% of sight-threatening GO patients. Other study only found 1.4% corneal ulcers in 1000 GO patients observed in 10 years.<sup>3,4</sup>

The management of this patient involves a collaborative procedure from different departments. First, we tried to control the inflammation using the 2016 European Group on Graves' Orbitopathy (EUGOGO) guideline of sight-threatening Graves' orbitopathy. The 2016 EUGOGO guidelines recommends intravenous high-dose glucocorticoids as the first line of treatment for moderate-to-severe and active Graves' Orbitopathy. The optimal cumulative dose appears to be 4.5–5 g of methylprednisolone. For this patient we use the recommendation of 500–1,000 mg of methylprednisolone for 3 consecutive days or on alternate days during the 1st week.<sup>5</sup>

Improvement of the clinical manifestation was met after the first initial dose of methylprednisolone, showing a good response to therapy. Based on the guideline intravenous methylprednisolone should be continued for the management of moderate-to-severe and active GO, which was 0.5 g once weekly for 6 weeks.<sup>5</sup>

For the corneal ulcer, we consulted to Infection and Immunology Department and the patient was given topical and oral antibiotics. Initial therapy consists of empiric, topical broad-spectrum coverage. But in this patient, no bacterial or fungal cells found from the corneal swab. This can be due to the patient had already administered topical antibiotic before and hasn't stopped the usage enough time before performing the corneal swab. We also applied amniotic membrane transplant graft on the patient's right eye, after we made sure that the infection was

not still active and no prolapse of the cornea.<sup>2,6</sup>

After the consultation to Department of Internal Medicine, this patient was diagnosed with Hyperthyroid without Thyroid Crisis (Grave's Disease) and also given an antithyroid drugs (metamizole) and propanolol.<sup>2</sup>

An orbital decompression should be performed if response is absent or poor within 2 weeks, but due to the improvement of the patient's condition, the procedure can be postponed. The high level of thyroid function also prevented the Department of Anaesthesiology to consider a general anesthesiology for this patient. Then, orbital wall decompression with general anesthesia will be planned after the thyroid function is stable.<sup>2</sup>

## CONCLUSION

Graves' orbitopathy is a self-limiting autoimmune process associated with dysthyroid states, and if left untreated can lead to a number of complications. Although rare, corneal ulcer is considered as sight-threatening complication of TED.

By following EUGOGO guideline protocol, the clinical condition of this patient improved, but the management of an active, sight-threatening Graves' Orbitopathy remains challenging and should be covered by multidisciplinary approach.

## REFERENCES

1. Weiler, D.L. 2016. Thyroid eye disease: a review. *Clin Exp Optom.* 100:20–25. DOI:10.1111/cxo.12472
2. Korn, B. S., Burkat, C. N., Carter, K. D., Perry, J. D., Setabutr, P., Steele, E. A., Vagefi, M. R. 2021. Orbital Inflammatory and Infectious Disorders. In: *Oculofacial Plastic and Orbital Surgery. Basic and Clinical Science Course 2021-2022.* American Academy of Ophthalmology. San Francisco. 53-62
3. Tramunt, B., Imbert, P., Grunenwald, S., Boutault, F., Caron, P. 2018. Sight -threatening Graves' orbitopathy: twenty years' experience of a multidisciplinary thyroid -eye outpatient clinic. *Clinical Endocrinology.* 90(1):208-213. DOI: 10.1111/cen.13880
4. Naik, M. N., Vasanthapuram, V. H., Joseph, J., Murthy, S. I. 2019. Microbial Keratitis in Thyroid Eye Disease: Clinical Features, Microbiological Profile, and Treatment Outcome. *Ophthalmic Plast Reconstr Surg.* 35(6):543-548. DOI: 10.1097/IOP.0000000000001361.
5. Bartalena, L., Baldeschi, L., Boboridis, K., Eckstein, A., Kahaly, G. J., Marcocci, C., Perros, P., Salvi, M., Wiersinga, W. M. 2016. The 2016 European Thyroid Association/European Group on Graves' Orbitopathy Guidelines for the Management of Graves' Orbitopathy. *Eur Thyroid J.* 5:9–26. DOI: 10.1111/cen.13880
6. Feder, S. F., Berdy, G. J., Iuorno, J. D., Marcovich, A. L., Mian, S. I., Reilly, C. D., Trief, D., Verdier, D. D. 2021. Bacterial, Fungal, and Parasitic Infections. In: *External Disease and Cornea. Basic and Clinical Science Course 2021-2022.* American Academy of Ophthalmology. San Francisco. 337-340