

CASE REPORT

Phacoemulsification with combination of CTR and Iris Hook in Subluxated Cataract

Muhammad Abdurrauf¹, Dicky Hermawan¹

¹Department of Ophthalmology, Faculty of Medicine, Airlangga University, Surabaya
E-mail: ag21rf@gmail.com

ABSTRACT

Purpose: To report a management of challenging case of phacoemulsification in cataract with subluxated lens.

Methods: A 63 male patient referred to RSDS with secondary lens induced glaucoma and cataract with subluxation around 210° on left eye. Patient was planned to undergo Phacoemulsification with combination of CTR and Iris Hook for lens extraction.

Result: Postoperative result is satisfactory with minimal corneal edema. After 6 weeks of follow-up uncorrected vision is 5/8 with correction of S+0.25 became 5/5 and IOP is stable at 17 mmHg and the IOL was in placed in the bag and well centered.

Conclusion: Phacoemulsification with iris hooks combined with CTR is one of surgery option that is safe and widely attainable for cataract with subluxated lens.

Keyword: Subluxated lens, secondary glaucoma, cataract, phacoemulsification

ABSTRAK

Tujuan: Melaporkan penanganan kasus fakoemulsifikasi yang menantang pada katarak dengan lensa subluxated.

Metode: pasien pria 63 tahun dirujuk ke RSDS dengan glaukoma yang diinduksi lensa sekunder dan katarak dengan subluksasi sekitar 210° pada mata kiri. Pasien direncanakan menjalani fakoemulsifikasi dengan kombinasi CTR dan Iris Hook untuk ekstraksi lensa.

Hasil: Hasil pasca operasi yang memuaskan dengan edema kornea yang minimal. Setelah 6 minggu follow up, penglihatan tanpa koreksi 5/8 dan dengan koreksi S + 0.25 menjadi 5/5 dan TIO stabil pada 17 mmHg dan IOL di dalam dalam kapsul lensa dan terpusat dengan baik.

Kesimpulan: Fakoemulsifikasi dengan iris hook yang dikombinasikan dengan CTR merupakan salah satu pilihan operasi yang aman dan dapat dilakukan secara luas untuk katarak dengan lensa subluxated.

Kata kunci: subluksasi lensa, glaukoma sekunder, katarak, fakoemulsifikasi

INTRODUCTION

Lens instability in cataract is a challenging case among phaco-surgeons. Lens may displace anteriorly that leads in decreasing

the depth of the anterior chamber. This results in crowding of the angle and possibly in pupillary block. Surgeries indicated for primary angle closure such as YAG iridotomy or peripheral iridotomy is

rarely effective in controlling the IOP in this case. Treatment of angle closure due to lens subluxation is extraction of the lens. In past times it is one of the limitations of phacoemulsification that requires surgeon to convert into “safer” procedures. ICCE or ECCE with scleral-fixated IOL has been suggested for these cases for past decades. However, the large surgical incisions may cause anterior chamber instability and result in surgical trauma and complications. However with recent advancement techniques and equipment, phacoemulsification surgery with proper precautions can be done in this case for more stable anterior chamber. ^(1,2)

Standard CTR is the pioneer of capsular support device. It redistributes capsular stress into entire capsule. CTR alone was mainly used for 120° zonular instability. ^(1,3) Cionni ring and Ahmed capsular tension segment was introduced as modified CTR to secure lens with more extensive zonular weakness. ^(4,5,6,7) These devices enabled support for lens capsule with secured sutured in the sclera. Advancement in capsular support device enabled implantation IOL “in the bag” for cataract with zonular weakness. ⁽³⁾ However these devices availability is limited especially in developing country like Indonesia. More common device that suggested to managing more extensive zonular weakness is combination of iris hook and CTR to secure zonular instability. ⁽⁸⁾

CASE ILLUSTRATIONS

A 63 male patient was referred to outpatient ward at RSDS complaining blurred vision on left eyes. He felt his vision was obscured with fog since 1 years ago with the fog is gradually thickened. At the time he was visited eye clinic his left eyes already unable to see. About 5 month before he felt sudden pain and redness on his left eye and came to ER near his house and given oral medication and get better. He then had another attack 2 month after first incidence and had same treatment. Patient

admitted that he didn't attend to ophthalmologist after the attack because he had no complaining prior the eye condition. Then patient felt his left vision is getting worse and came to ophthalmologist near his house and referred to dr. Sutomo General Hospital. There is history of hypertension and diabetes for nine years, coronary heart disease for one year, stroke attack on 2011 and 2016. There is no history of ocular trauma, prior vitrectomy, prior trabeculotomy, high myopia, marfan syndrome, elastic skin, skin that bruised easily, flush cheek. From general examination there is no brachydactyly, his build is not tall and slender, no arahnodactyly. Visual acuity was 6/7,5 with correction S-4.00 on right eye and hand movement on left eyes. The IOP on right eye was 17 on right eye and 23 on left eye with therapy of anti-glaucoma agent from previous ophthalmology. From the slitlamp examination found on right eye deep COA with VH III and minimal opacity on the lens (LOCS III NO2NC2C1P1), while on left eye was found shallow COA with VH I and opaque lens (LOCS III NO5NC5C1P1). On the left eye the lens was subluxated anteriorly for around 2-3 quadrants. There were no fibrin deposit on iris and the lens. Funduscopy examination on left eye couldn't evaluate due to cataract, while right eye within normal limits. There was no suggestion of myopic eyes on from funduscopy examination. USG examination was performed on left eyes with normal result. Biometri on left eye revealed patient had ACD 2.34 mm with LT 4.83 mm

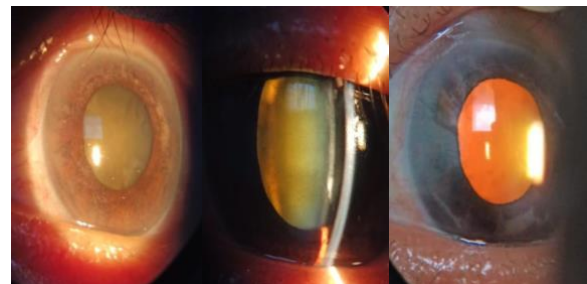


Fig 1. Anterior segment of left eye on left diffuse illumination, center slit illumination, right retro illumination

The patient then was planned to undergo phacoemulsification and IOL implantation. CTR and iris hook was prepared in advance to maintaining lens stability during surgery. If phacoemulsification couldn't be performed due to instability of the lens the surgery was planned to convert into ECCE/ICCE.

Surgery Report

Main port was made using 2,75 mm clear corneal incision. Trypan blue was injected to staining the capsule, than viscoelastic was injected. Capsulorexis was done with cautions using utrata. During capsulorexis the surgeon noted that capsular instability around 7 clockhours (210°). After capsulorexis was completed, CTR was inserted to stabilize the lens. Second port was made perpendicular with main incision. Iris hook then placed under anterior capsule on 2,5,7 and 11 clock hour to stabilize lens. After surgeon felt the lens was relatively stable phacoemulsification was done on low parameter (CV9000R, Nidek, Inc). After initial cracking lens was brought to anterior chamber, then it emulsified and aspirate cautiously. Then foldable IOL was inserted in the bag. The operation was ended with injection of carbachol and cefuroxime intracamerall.

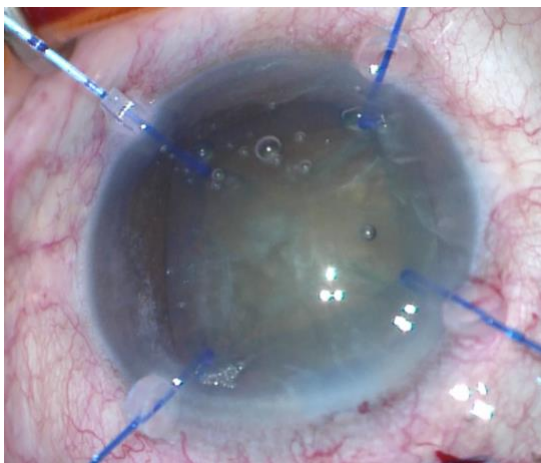


Fig 2. Iris hook was used for maintaining lens stability with CTR already placed inside capsular bag

Postoperatively patient was given Levofloxacin and Fluorometholone eye drop every 3 hours on left eye, Ciprofloxacin oral 500 mg every 12 hours, Mefenamic Acid oral 500 mg every 8 hours and Timolol eye drop every 12 hours on left eye. Postoperative result was satisfactory with corneal edema was present for 2 weeks after surgery. After 6 weeks post surgery visual acuity on left eye was 5/8 and with correction of S+0.25 became 5/5 with IOP postoperative able to be maintained at 17 mmHg and IOL is on place and well centered in the bag.

DISCUSSION

In this patient the lens is intumescent and subluxated anteriorly that closing the angle. Even though glaucoma medication of aqueous suppressant the IOP is still uncontrolled. Thus lens extraction in this situation should be done. However with zonular instability makes cataract extraction in this case challenging. Inappropriate approach of surgery may cause lens to drop backward into posterior and might causing further complications. (1,2)

With recent advancement of surgical technique and instrument, limitations on phacoemulsification surgery now lessen. For instance, with proper approach lens with inadequate zonular support was able to be extracted using phacoemulsification technique. Usage of CTR, Cionni ring, Malyugin-Cionni ring, Ahmed segment, capsular anchor and Mackool capsule retractors was introduced to stabilize the lens. However most of the mentioned instrument wasn't widely available. (9)

Iris retractor was initially used to stabilize lens on patient with pseudoexfoliative syndrome. Phacoemulsification with use of iris retractor was reported safe procedure to be done in subluxated lens. It stretches the capsule to maintain tension to hold the capsule in place. Combination of 4-5 iris hooks and CTR ensures centration of

capsular bag and capsular expansion in 360° that provides “in the bag” IOL implantation option. ^(9,10,11)

The implantation of CTR immediately after capsulorexis is completed ensures higher safety of remaining procedures because of equal distribution of force by the ring and stabilization of the capsular bag. However the removal of lens material that trapped under capsular ring became difficult and sometimes retained some lens material that stuck. However with the risk in this patient it still have greater beneficial early placing of the CTR. ^(12,13)

In combined technique of CTR and iris hook it is important to make sure capsulorexis is round and perfect. Insertion of CTR and iris hook may further tear the anterior capsule. Use of a CTR and iris hooks are not recommended if the capsulorexis isn't round and done continuously. It is also not recommended if the anterior and posterior capsules have not been preserved ⁽⁸⁾

Other alternative, Cionni ring was used to secure lens capsule in place. This method provides safer options for the patient because the capsule is fixated in the sclera. ⁽¹⁴⁾ However this instrument isn't available on our operating room at that time.

In conclusion in our patient phacoemulsification is less invasive than ICCE/ECCE thus reduced complication rate and improved functional result. Phacoemulsification with iris hooks combined with CTR is one of option that widely attainable to be considered.

ACKNOWLEDGEMENTS

This study received no specific grant from any funding agency or institution.

REFERENCES

1. Murray AD. An Approach to Some As1. Jick SL, Beardsley TL, Brasington CR, Buznego C, Grostern RJ, Park L, et al., ed.

Lens and cataract BCSC 2019-2020. 2019–2020 ed. San Francisco: American Academy of Ophthalmology; 2019: 92, 207-210.

2. Luo L, Li M, Zhong Y, et al. Evaluation of secondary glaucoma associated with subluxated lens misdiagnosed as acute primary angle-closure glaucoma. *J Glaucoma*. Apr-May 2013;22(4):307-10.
3. Assia EI, Ton Y, Michaeli A. Capsule anchor to manage subluxated lenses: Initial clinical experience. *J Cataract Refract Surg*. 2009 Aug;35(8):1372-9.
4. Cionni RJ, Osher RH, Marques DMV, Marques FF, Snyder ME, Shapiro S. Modified capsular tension ring for patients with congenital loss of zonular support. *J Cataract Refract Surg* 2003; 29:1668–1673
5. Cionni RJ, Osher RH. Management of profound zonular dialysis or weakness with a new endocapsular ring designed for scleral fixation. *J Cataract Refract Surg* 1998; 24:1299–1306
6. Hasanee K, Ahmed KII. Capsular tension rings: update on endocapsular support devices. *Ophthalmol Clin North Am* 2006; 19(4):507–519
7. Hasanee K, Butler M, Ahmed K II. Capsular tension rings and related devices: current concepts. *Curr Opin Ophthalmol* 2006; 17:31–41.
8. Santoro S, Sannace C, Cascella MC, Lavermicocca N. Subluxated lens: phacoemulsification with iris hooks. *J Cataract Refract Surg* 2003; 29:2269–2273
9. Kopsachilis N, Carifi G. Phacoemulsification using 8 flexible iris hooks in a patient with a short eye, small pupil, and phacodonesis. *J Cataract Refract Surg*. 2014;40(9):1408-1411. doi:10.1016/j.jcrs.2014.07.009
10. Chang DF. Phacoemulsification in high-risk cases. In: Wallace RB III, ed, *Refractive Cataract Surgery and Multifocal IOLs*. Thorofare, NJ, Slack, 2001; 121–136
11. Hoffman RS, Snyder ME, Devgan U, et al. Management of the subluxated crystalline lens. *J Cataract Refract Surg*. 2013;39(12):1904-1915. doi:10.1016/j.jcrs.2013.09.005

12. Chee SP, Jap A. Management of traumatic severely subluxated cataracts. *Am J Ophthalmol.* 2011;151:866–871
13. Ma X & Li. Capsular tension ring implantation after lens extraction for management of subluxated cataracts. *Int J Clin Exp Pathol.* 2014; 7(7): 3733–3738.
14. Buttanri, I. B., Sevim, M. S., Esen, D., Acar, B. T., Serin, D., & Acar, S. . Modified capsular tension ring implantation in eyes with traumatic cataract and loss of zonular support. *J Cataract Refract Surg.* 2012: 38(3), 431–436.