

CASE REPORT

Surgical Result of Goniotomy on Primary Congenital Glaucoma in Indonesia Patient

Arini Safira Nurul Akbar, Virawardhana Istiantoro, Florence Meilani Manurung

Jakarta Eye Center Eye Hospitals and Clinics

E-mail: arinisafira@gmail.com

ABSTRACT

Objective: To present a case of goniotomy procedure and angle imaging on primary congenital glaucoma (PCG) in Indonesian patient.

Case presentation: a 6 month old baby presenting with enlarged left eye since birth. The ophthalmological examination found good light and object fixation on both eyes. The eyes were orthophoric. There was no nystagmus and movement restriction. The corneal diameter of the right eye was 10 mm and the left eye was 13 mm. Haab striae (+) on left eye. The intraocular pressure (IOP) was 11 mmHg on right eye and 35 mmHg on left eye. There were no other abnormalities on both eyes. A goniotomy procedure was done on the left eye. The IOP of the left eye on 1 day, 1 week and 3 month post surgery were 6, 18 and 17 mmHg respectively. The cornea of the left eye was clear despite the Haab striae dan bruckner test was good. Optic nerve head examination of the left eye was good and the cup to disk ratio was 0.5.

Conclusions: Surgical therapy is usually warranted in the management of PCG. Goniotomy is typically chosen as the initial surgery when the refractive media is clear and direct visualization of the angle is visible. The advantage of goniotomy over other angle surgeries for PCG is spare of the conjunctiva for filtration surgery if required in the future. Our case of goniotomy on PCG in Indonesian patient showed good results and promising prognosis post procedure.

Keywords: Primary congenital glaucoma, goniotomy

Primary congenital glaucoma (PCG) is a rare disease affecting children early in life which constitutes a diagnosis and therapeutic challenge to ophthalmologists.^{1,2} In the western countries, the incidence of PCG lies within 1:10000 to 1:70000 while in Asian and subsaharan countries the incidence is higher, between 1:1250 and 1:3300.² This is thought to be due to higher incidence of consanguinity. In Indonesia, childhood glaucoma was one of the major causes of treatable blindness in a study at schools for the blind in Java.³

Childhood glaucoma is defined as PCG when an isolated and idiopathic developmental anomaly of the anterior

chamber angle exists and no other ocular or systemic abnormalities occur.⁴ The management of PCG generally and practically always required surgical procedure. Angle surgeries, for instance, goniotomy and trabeculotomy were introduced in the middle part of the 20th century and both procedures have traditionally been considered as procedures of choice because of high reported success rate.⁵ Success rate of these angle surgeries can be as high as 70-80% cases with PCG diagnosed between 3-12 months of age.⁶ Other filtration surgery such as trabeculectomy and glaucoma drainage device implantation should be reserved for congenital glaucoma cases in which angle surgeries have failed.^{1,2,6}

Studies regarding the treatment of congenital glaucoma, especially PCG, or any case reports with reference to PCG and its management in Indonesian patients are still very limited. This study intended to report a successful case of PCG management with goniotomy procedure in an Indonesian patient.

CASE PRESENTATION

A 6 month old male baby presented to our hospital with a chief complaint of enlargement of the left eye since 1 month before admission. He was referred by his pediatrician due to buphthalmos and epiphora. There was slight blepharospasm and photophobia. The parents reported that despite the enlargement of the left eye, both of the eye coordinated symmetrically. There was no family history of glaucoma and consanguinity. The pregnancy and delivery history of the patient were unremarkable. The patient had 2 siblings and both of his siblings had normal growth and development. The ophthalmological examination found good light and object fixation on both eyes. The eyes were orthophoric. There was no nystagmus and movement restriction on both eyes. The corneal diameter of the right eye was 10 mm and the left eye was 13 mm. Haab striae was found on left eye cornea (figure 1).

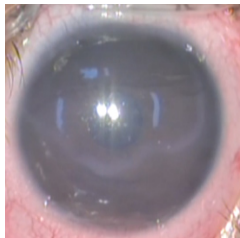

Fig 1. The patient was presented with buphthalmos and Haab striae

The presenting intraocular pressure (IOP) was 10 mmHg on right eye and 35 mmHg on left eye. There were no other abnormalities on both eyes or other part of the body. An examination under general anaesthesia and goniotomy procedure was planned on the left eye. The patient was given topical antiglaucoma medication i.e brinzolamide twice daily and latanoprost

once daily on the left eye to decrease the IOP before surgery. The goniotomy procedure was done 1 week after the first presentation under general anaesthesia. Before the procedure we captured the image of the affected angle which showed immature development of the angle (figure 2).

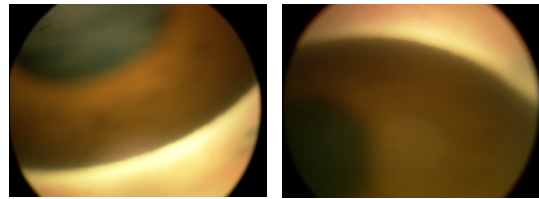


Fig 2. Retacam gonioscopic imaging of the affected eye showed immature development of the angle.

The fellow eye showed normal structural development of the angle (figure 3).

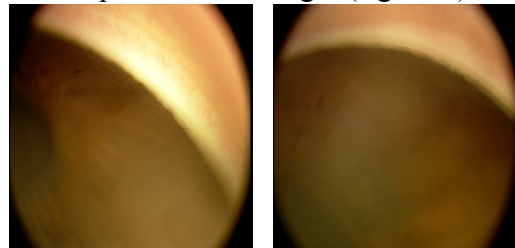


Fig 3. Retacam gonioscopic imaging of the fellow eye showed normal structural development of the angle

We performed the goniotomy in 180° of the angle using a needle knife. A gonioscope was used to visualize the angle. Fundus examination of the left eye revealed good optic nerve with thick rim and cup to disk ratio 0.5. The antiglaucoma medication was stopped after completion of the surgery.

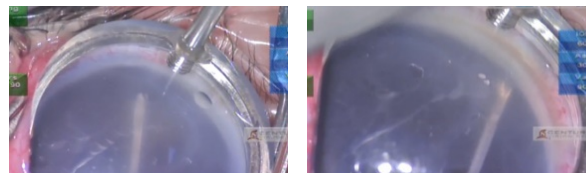

Fig 4. Goniotomy was performed in 180° of the angle using a needle knife and gonioscope for angle visualization

The patient was given topical levofloxacin hourly for the first day then continued 3 hourly and also topical flumetholone 3 hourly. On 1 week post procedure, the IOP was 18 mmHg and the cornea was clear. The topical steroid was tapered off into 4 times daily for 3 weeks. The Bruckner test was good and revealed symmetrical red reflex in both eyes. Examination on 1 and 3 month after surgery showed good result with IOP 16 and 17 mmHg respectively. The examination of the fellow eye was also within normal limits.

DISCUSSION

Primary congenital glaucoma is a rare but important disease which can lead to blindness if presented late and with severe damage, or alternatively a lifetime vision with early diagnosis and prompt treatment to control IOP.⁶ Primary congenital glaucoma refers to childhood glaucoma due to isolated trabeculodysgenesis where the angle is maldeveloped with an absence of angle recess and iris insertion directly onto the trabecular meshwork.^{1,2,6} Primary congenital glaucoma may present at birth or before 1 month of age (newborn PCG), within the first 2 years of life (infantile PCG), or between 2-4 years of age (late-diagnosed PCG).

We reported a case of unilateral infantile PCG with onset at 5 months of age with a chief complaint of buphthalmos on the left eye. The patient also experienced epiphora, blepharospasm and photophobia. These symptoms are known as the classical triad of congenital glaucoma.^{1,2,6} Typical signs of congenital glaucoma such as high IOP (35 mmHg), increased corneal diameter (13 mm) and Haab striae were also found in the patient. Primary congenital glaucoma should be distinguished from other anterior segment disorder and syndromes which may be associated with glaucoma such as aniridia, Peters anomaly, Axenfeld-Rieger syndrome, microphthalmos, Sturge-Weber and others.⁶ It is important to examine

thoroughly other part of the eye that is the iris, lens and cornea for associated findings. Facial features and other body part needs to be evaluated as well to rule out systemic issues. The gonioscopy examination performed under general anaesthesia and revealed the typical maldevelopment of the angle in the affected eye. The iris inserted anteriorly and has a scalloped appearance.¹⁻⁶ There were no other anatomical abnormalities present on the patient. The fellow eye also showed no pathology and abnormalities. Primary congenital glaucoma is usually bilateral but it can also be unilateral or asymmetrical in 20-30% cases.⁷

The definitive management of PCG is surgical due to less efficacy of medical treatment compared to adults. Medical treatment is also less tolerated on the long term in pediatric patients.^{6,8} Two angle procedures generally performed on PCG are goniotomy and trabeculotomy. These procedures address the angle anomaly in PCG and increase outflow of aqueous humour by connecting Schlemm's canal directly to the anterior chamber.⁸ Both of these procedures are appropriate if the cornea is clear. If the cornea is cloudy, goniotomy is difficult to do because of poor visualization of the angle, thus trabeculotomy is more easy to performed. We performed goniotomy on this patient because of the relatively clear cornea that able us to visualize the angle and do the procedure. Goniotomy is also the procedure of choice in PCG because it preserves the conjunctiva thus does not risk the success of future filtering surgery that may needed and carries no long term risk of bleb-related complications.^{6,8} The success rate of goniotomy in varied between 40% to 90% depending on the number of goniotomies required, the initial severity of the disease and presence of corneal cloudiness at presentation.^{1,2,4,6,8} With proper case selection, the outcomes of goniotomy are satisfactory. The main factors influencing the success are the timing of diagnosis (onset), where the higher success rate was observed among

those who present between 3-12 months of age (infantile PCG).⁶ Our case showed good result of controlled IOP post operatively without any glaucoma medications. The fundus examination of the affected eye found a considerably good optic nerve head with cup to disk ratio 0.5 which gave a promising and good visual prognosis.

However, continuous follow up and evaluation is of utmost importance to ensure optimal visual prognosis.^{1,6,9} Visual prognosis in PCG depends on severity of the disease at diagnosis and the response to intervention with successful control of IOP on follow up.⁶ In addition to that, a 23-years cohort study found that good IOP control does not necessarily predict good visual outcome in PCG.⁹ At birth or less than 1 month of age at presentation resulted in worse visual prognosis. Eventhough glaucomatous cupping can be reversed in younger age but visual acuity is often poor due to structural and functional complications including corneal scarring, myopia, astigmatism, anisometropia and irreversible glaucomatous optic neuropathy.^{1,6,9} Hence, beside IOP measurement and optic nerve evaluation, management of the risk factors of amblyopia mentioned above is essential in follow up evaluation of PCG. The cohort study also found that after initial angle surgeries within the first years of life, there appears to be repeat surgeries clustered around 2-3 and 5-6 year age groups. These year age group may represent the critical time points of glaucoma progression after previous successful angle surgery and warrant a close observation and follow up.⁹

CONCLUSION

Primary congenital glaucoma is a rare disease that can lead to blindness without prompt treatment. Early detection and timely diagnosis are essential to increase the chances of successful outcome. Surgical therapy is usually warranted in the management of primary congenital glaucoma. Goniotomy is typically chosen as the initial surgery when

the refractive media is clear and direct visualization of the angle is visible. The advantage of goniotomy over other angle surgeries is that the conjunctiva is spared for future filtration surgery if warranted and has low risk of long term complications. Our case of goniotomy on primary congenital glaucoma in Indonesian patient showed good results and promising prognosis post procedure. Nevertheless, continuing follow up and evaluation is needed to ensure and sustain the good visual prognosis of the patient.

REFERENCE

1. Badawi AH, Al-Muhaylib AA, Al Owaifeer AM, Al-Essa RS, Al-Shahwan SA. Primary congenital glaucoma: an updated review. *Saudi Journal of Ophthalmology* 2019; 33:382-8
2. Chan JYY, Choy BNK, Ng ALK, Shum JWH. Review on the Management of Primary Congenital Glaucoma. *J Curr Glau Pract* 2015;9:92-9
3. Sitorus RS, Abidin MS, Prihartono J. Causes and temporal trends of childhood blindness in Indonesia: study at schools for the blind in Java. *Br J Ophthalmol* 2007;91:1109-1113
4. Ben-Zion I, Tomkins O, Moore DB, Helveston EM. Surgical results in the management of advanced primary congenital glaucoma in a rural pediatric population. *Ophthalmol* 2011;118:231-5
5. Khalil DH, Abdelhakim MASE. Primary trabeculotomy compared to combined trabeculectomy-trabeculotomy in congenital glaucoma: 3-year study. *Acta Ophthalmol* 2016;94:550-4
6. Ko F, Papadopoulos M, Khaw PT. Primary Congenital Glaucoma. *Prog in Brain Res* 2015;221:177-189
7. Bayoumi NHL. Fellow eye in unilateral primary congenital glaucoma. *J Curr Glau Pract* 2017;11(1):28-30
8. El Sayed Y, Esmael A, Mettias N, El Sanabary Z, Gawdat G. Factors influencing the outcome of goniotomy and trabeculotomy in primary congenital glaucoma. *Br J Ophthalmol* 2019;0:1-6
9. Zagora SL, Funnell CL, Martin FJ, Smith JEH, Hing S, Billson FA et al. Primary congenital glaucoma outcomes: Lessons from

23 years of follow up. Am J Ophthalmol
2015;159:788-79