

## CASE REPORT

# Internuclear Ophthalmoplegia with Ipsilateral Abduction Deficit : Half and Half Syndrome

Ulfah Rimayanti<sup>1,2</sup>, Yunita<sup>1,3</sup>, Batari T Umar<sup>1,3</sup>

<sup>1</sup>Departement of Ophthalmology, Faculty of Medicine, Universitas Hasanuddin, Makassar

<sup>1</sup>Study Program of Medicine, Faculty of Medicine and Health Science, UIN Alauddin, Makassar

<sup>3</sup>Departement of Ophthalmology, Dr. Wahidin Sudirohusodo Hospital, Makassar

E-mail: rimayantiu@gmail.com

## ABSTRACT

**Introduction :** Head trauma can often result in diplopia. Internuclear ophthalmoplegia (INO) coexists with ipsilateral abduction deficit, introduced as half and half syndrome, is rarely reported.

**Case Presentation :** A 17-year-old male came with binocular diplopia on horizontal gaze 2 days after a head trauma. Best corrected visual acuity on both eyes were 6/6. Adduction deficit of contralateral gaze appeared on the right eye associated with an abducting dissociated horizontal nystagmus on the left eye. He also had a moderate under-action of abduction on ipsilateral gaze of the right eye. On up gaze, both eyes were found to have vertical nystagmus. Anterior and posterior segments revealed normal, except minimal chemosis on the right eye, no relative afferent pupillary defect. Brain imaging showed lesions in pons mainly on the right side. Observation and conservative management were done.

**Results :** Improvement of ocular movement was observed in 2 weeks. However, diplopia and mild ocular movement limitation were still found after 6 months.

**Conclusion :** Based on ophthalmologic and systemic examinations the patient had internuclear ophthalmoplegia (half) with ipsilateral abduction deficit (half): half and half syndrome. Head trauma is one of the risk factors of ocular motility disorders.

**Keywords:** *Half and half syndrome, internuclear ophthalmoplegia, abduction deficit, diplopia*

Head trauma can often result in occurrence of diplopia. Internuclear ophthalmoplegia (INO), a disorder defined as medial rectus limitation or obvious slowing, often accompanied by dissociated nystagmus of the fellow eye.<sup>1</sup> The nature of the lesion varies greatly, however, the two major causes of INO in adults are brainstem ischemia/infarction and multiple sclerosis.<sup>2</sup> Head trauma is a rare cause,<sup>3</sup> but increasingly recognized, especially in males: about half are bilateral INO and half unilateral, and most are due to

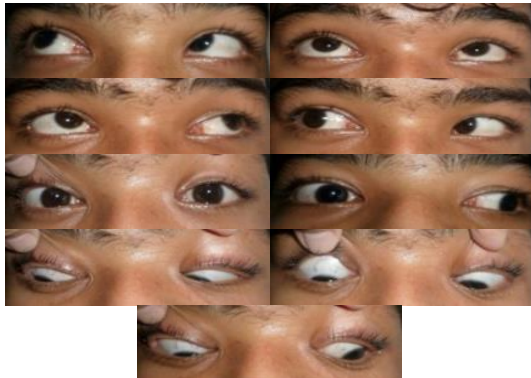blunt trauma, penetrating trauma or trauma on neck/vertebral artery.<sup>2,4</sup>

Internuclear ophthalmoplegia coexists with ipsilateral abduction deficit is rarely reported. The concurrent disorder was first reported by Randhawa et al in 2007 in a patient with hemorrhagic lesion in pons after a head trauma. They introduced it as half and half syndrome; to our knowledge, there were 2 cases reported previously. It was found in patient with trauma and stroke with presumed lesion in MLF and sixth nerve fasciculus.<sup>5,6</sup> This report presents an INO case with ipsilateral abduction deficit after a head trauma.

## CASE PRESENTATION

A 17-year-old male who was referred from Neurosurgery Department with binocular diplopia after head trauma. Diplopia on horizontal gaze has been complained since 2 days after trauma. He had no history of wearing spectacles, systemic diseases and neurologic symptoms.

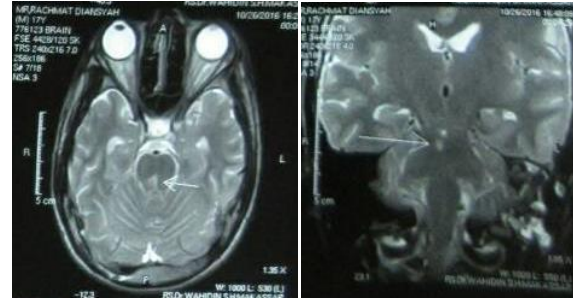
Best-corrected visual acuity on both eyes were 6/6. Pupils were normal and no relative afferent pupillary defect was found. There was adduction deficit of contralateral gaze on the right eye associated with an abducting dissociated horizontal nystagmus on the left eye. Both eyes adducted normally in convergence. These signs were consistent with INO. He also had a moderate underaction of ipsilateral abduction on the right eye and overaction on down gaze (Figure 1). On up gaze, both eyes were found to have vertical nystagmus. Anterior segment revealed normal limit, except minimal chemosis on the right eye. The fundoscopic examination result of both eyes were within normal limit.



**Fig 1.** Photographs of eye movement show adduction and abduction limitations of the right eye 2 days after head trauma

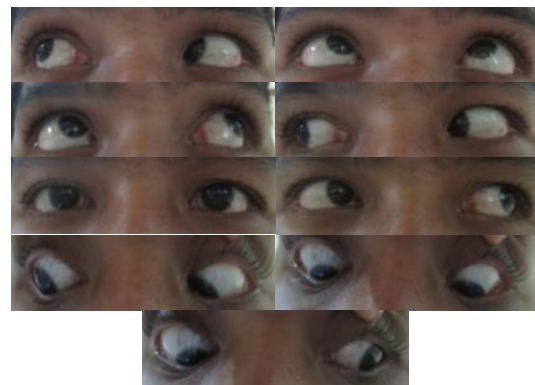Brain MRI showed isointense lesion in sagittal view T1 weighted image, hyperintense lesions in axial view T2 weighted image, lesions in pons mainly on the right side

the right side (suspected as hematome), left hematomastoid DD/ left mastoiditis, and right hypertrophic rhinitis (Figure 2). Laboratory examination results were within normal limit.



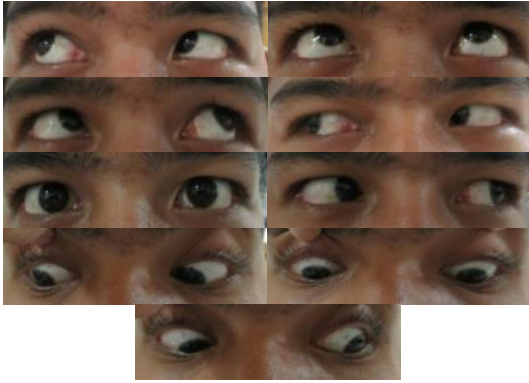**Fig 2.** Brain MRI showed isointense lesion in sagittal view T1 weighted image, hyperintense lesions in axial view T2 weighted image, lesions in pons mainly on the right side

There was no specific management for this patient. Observation with conservative management by giving neuroprotector agent was done. There was improvement of ocular movement in 2 weeks after treatment (Figure 3).



**Fig 3.** Photographs of eye movement show adduction and abduction improvement of the right eye 2 weeks after head trauma

Six months after trauma, abduction limitation still existed on the right eye, with normal adduction, thus the patient still had minimal diplopia especially on the right gaze compared to the left gaze. Anterior segments were within normal limit. There was no abnormality was found on his head CT-scan.

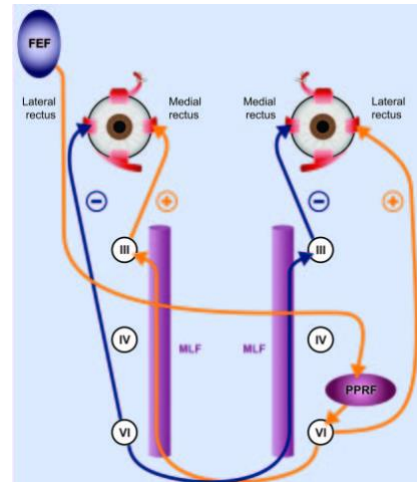


**Fig 4.** Photographs of eye movement 6 months after trauma show abduction limitation with normal adduction of the right eye

## DISCUSSION

The half and half syndrome consists of an internuclear ophthalmoplegia (“half” of a contralateral horizontal gaze palsy) and an ipsilateral sixth cranial nerve fascicular involvement (“half” of an ipsilateral horizontal gaze palsy).<sup>5</sup> The pathway of horizontal saccadic eye movement is described in Figure 5. Internuclear ophthalmology is caused by injury to the medial longitudinal fasciculus (MLF) in the brainstem. Medial longitudinal fasciculus is a bundle of fibers that connects the sixth nerve nucleus on one side of the pons to the medial rectus subnucleus (of the third nerve) on the contralateral side of the midbrain. Therefore, INO results in adduction limitation of medial rectus muscle.<sup>7</sup> Our patient had an adduction underaction on the right eye and an abducting dissociated horizontal nystagmus on the left eye, suitable for INO signs.

The affected eye adducts normally in convergence eye movement. This finding distinguishes INO from the third cranial nerve palsy, which impairs adduction in convergence.<sup>8</sup> The oculomotor nerve palsy also can cause limited vertical eye movement, ptosis, and pupillary abnormalities.



**Fig 5.** Pathway of horizontal saccadic eye movement. Excitatory pathways are shown in orange and the reciprocal inhibitory pathways are shown in blue. FEF: frontal eye field (Courtesy of Frohman TC, et al)

Half and half syndrome also differs with one-and-a-half syndrome which combines a horizontal gaze palsy and ipsilateral INO. This syndrome involves the MLF and the paramedian pontine reticular formation (PPRF) (or the sixth nerve nucleus) on the same side of the brainstem. Thus, the only horizontal eye movement remaining is abduction of the eye contralateral to the lesion.<sup>9</sup>

Ipsilateral horizontal gaze palsy in our patient was predicted to be caused by lesion the the abducens nerve fasciculus. Abducens nerve components are nucleus, fasciculus, basilar, intracavernous, and intraorbital parts. Fasciculus emerging from the nucleus course forward through the pontine tegmentum, passes ventrally to leave the brainstem at the pontomedullary junction.<sup>10</sup> Common causes of fascicular lesions include infarction, compression, demyelinating disease, and less likely causes are hemorrhage, trauma, and infection.<sup>11</sup> Fascicular lesions of abducens nerve result in ipsilateral abduction dysfunction.<sup>12</sup>

The ocular motor disorder in half and half syndrome can be in horizontal or vertical gaze.<sup>5,6</sup> At the first examination, our patient

had abduction and adduction deficits on his right eye, with horizontal gaze diplopia as the patient chief complaint. Horizontal diplopia, without vertical separation, is related to the impaired neural control or function of the medial rectus muscle, the lateral rectus muscle, or both.<sup>13</sup>

Our patient presented with bilateral vertical nystagmus on up gaze. Gaze evoked nystagmus, a jerk nystagmus present only on eccentric gaze but not in the primary position, is commonly seen and has limited localizing value. Patients with MLF lesions may have a dissociated vertical nystagmus.<sup>7</sup> Bilateral vertical gaze evoked nystagmus commonly occurs with structural brainstem and cerebellar lesions, diffuse metabolic disorder, and drug intoxication.<sup>13</sup>

In our patient, lesion suspected as hematoma was found in the dorsal caudal pons, mainly on the right side. This location could indicate damage to the abducens or facial nuclei, or any pathway traveling through the dorsal pontine tegmentum.<sup>14</sup> A pontine tegmental infarction frequently results in horizontal gaze palsy.<sup>15</sup> The pontine tegmentum contains neural structures for controlling horizontal eye movements, including the abducens nucleus and fascicle, paramedian pontine reticular formation, and MLF.<sup>13</sup>

The pathogenesis of the isolated damage to the MLF associated with head trauma is unclear, but several mechanisms have been suggested. Common hypotheses on the anatomical origin of post-traumatic MLF injury include differential displacement of the brainstem with resultant stretching of the MLF fibers, shearing forces in the brain stem caused by a blow to the head,<sup>16</sup> and shearing forces caused by the angular acceleration or deceleration of the head upon impact.<sup>17</sup> The shearing forces within the brainstem can damage the branches of the basilar artery, resulting in decreased blood flow or focal brainstem hemorrhage.<sup>18</sup> In

addition, the formation of a subdural hematoma causes a mass effect on the MLF fibers.<sup>16</sup> The shearing forces leading to hemorrhage and mass effect of hematoma may explain the pathogenesis of INO in our patient.

Our patient had INO with ipsilateral abduction deficit of which the lesion was found in the dorsal pons. We postulate that the lesion involved the right medial longitudinal fasciculus and the sixth nerve fasciculus.

Treatment options for half and half syndrome were not mentioned in the previous reports. With conservative management, the symptom and signs improved, but not resolved completely in our patient. The symptoms of INO after head trauma usually resolve with conservative management after a few months, but sometimes it can persist for more than a year.<sup>3</sup> Another study with more than 12 months follow-up found that patients with multiple sclerosis, infection or trauma recovered about 60-70% of the time. Recovery was less likely if the lesion causing the INO was visible.<sup>19</sup>

## CONCLUSION

Based on ophthalmologic and systemic examinations the patient had INO (half) with ipsilateral abduction deficit (half): half and half syndrome. Head trauma is one of the risk factors of ocular motility disorder; half and half syndrome is still rarely reported. Management option for this case is conservative and observation as spontaneous improvement was expected to occur.

## REFERENCES

1. Bamford R, Singh-Ranger G. Unilateral internuclear ophthalmoplegia after minor head injury. *West J of Emerg Med* 2012;13:123-4.
2. Keane JR. Internuclear Ophthalmoplegia. Unusual Causes in 114 of 410 Patients. *Arch Neurol.* 2005;62:714-7.

3. Constantoyannis C, Tzortzidis F, Papadakis N. Internuclear ophthalmoplegia following minor head injury: a case report. *Br J Neurosurg* 1998;12:377-9.
4. Doe JWt, Jay WM. Traumatic unilateral internuclear ophthalmoplegia. *Semin Ophthalmol* 2006;21:245-53.
5. Randhawa S, Shah VA, Kardon RH, Lee AG. An internuclear ophthalmoplegia with ipsilateral abduction deficit: half and half syndrome. *J Neurol Neurosurg Psychiatry*. 2007;78:309.
6. Ahdab R, Riachi N. Vertical 'half-and-a-half' syndrome. *J Neurol Neurosurg Psychiatry*. 2012;83:834-835.
7. Frohman TC, Galetta S, Fox R, et al. Pearls & Oysters: The medial longitudinal fasciculus in ocular motor physiology. *Neurology*. 2008;70:e57-67.
8. Gizzi M, Kastner B. Vision Problems Associated with Multiple Sclerosis. In: Silverstone B, Lang MA, Rosenthal BP, et al. *The Lighthouse Handbook on Vision Impairment and Vision Rehabilitation*. 2000. Oxford: Oxford University Press. pp.503-515.
9. Cantor LB, Rapuano CJ, Cioffi GA, et al. The Patient with Diplopia. In: *American Academy of Ophthalmology, Neuro-ophthalmology*. San Francisco: American Academy of Ophthalmology pp.280-314.
10. Marais W, Barrett S. An overview of the third, fourth and sixth cranial nerve palsies. *CME*. 2013;31:147-152.
11. Donahue SP. Nuclear and fascicular disorders of eye movement, in: Yanoff & Duker. *Ophthalmology*. 2009. Philadelphia: Elsevier Saunders. pp.922-926.
12. Gorthi SP, Venkatraman S. Disorders of cranial nerves. In: Munjal YP, et al. *Textbook of Medicine*. 2012. Mumbai: API. pp.1390-1400.
13. Danchaivijitr C, Kennard C. Diplopia and eye movement disorders. *J Neurol Neurosurg Psychiatry*. 2004 75: iv24-iv31.
14. Leigh RJ, Zee DS. *The neurology of eye movements*. Fourth ed. 2006. New York: Oxford University Press.
15. Lee E, Kim JS, Kim JS, et al. A small dorsal pontine infarction presenting with total gaze palsy including vertical saccades and pursuit. *J Clin Neurol*. 2007 Dec;3(4):208-11.
16. Devereaux MW, Brust JC, Keane JR. Internuclear ophthalmoplegia caused by subdural hematoma. *Neurology* 1979;29:251-255.
17. Hardman JM. The pathology of traumatic brain injuries. *Adv Neurol* 1979;22:15-50.
18. Jung DS, Park KP. Posttraumatic bilateral internuclear ophthalmoplegia with exotropia. *Arch Neurol* 2004;61:429.
19. Bolanos I, Lozano D, Cantu C. Internuclear ophthalmoplegia: causes and long-term follow-up in 65 patients. *Acta Neurol Scand* 2004;110(3):161-5.
20. Holmes JM, Beck RW, Kip KE, Droste PJ, Leske DA. Predictors of nonrecovery in acute traumatic sixth nerve palsy and paresis. *Ophthalmology* 2001;108(8):1457-60.