

CASE REPORT

Anti Tuberculosis Therapy Combined with Oral Corticosteroid and Intra Vitreal Anti-VEGF in Ocular Tuberculosis

Ira Aldita, Junaedi Sirajuddin, Sitti Soraya Taufik, A Muhammad Ichsan

Department of Ophthalmology, Faculty of Medicine, Hasanuddin University, Makassar

Dr. Wahidin Sudirohusodo Hasanuddin Hospital, Makassar

E-mail: dr.iraldita@gmail.com

ABSTRACT

Objective : To report a late diagnosed case of posterior uveitis tuberculosis and to create awareness to ophthalmologists for treating ocular tuberculosis as soon as possible.

Case Presentation : A 17-year old woman with a complaint of decreased vision in both eyes for the past 5 days. She had a history of non-purulent cough. In the initial examination, the patient was diagnosed and treated with papil edema and chorioretinitis with sub-retinal abscess and swollen disc, but she did not show any improvement. The patient was referred to the other ophthalmologist and diagnosed with ocular and systemic tuberculosis infection with choroidal neovascularization. The infection in the macula affected and aggravated visual acuity of counting finger at 1 meters. Anti-tuberculosis, oral corticosteroid and intravitreal anti-VEGF therapy were performed. The treatment showed significant improvement toward visual outcome and retinal condition.

Conclusion : Treatment with oral corticosteroid treatment along the systemic tuberculosis medication and intravitreal anti-VEGF showed good outcome on the right eye but deteriorated on the fellow eye.

Keywords : *tuberculosis, ocular tuberculosis, uveitis tuberculosis, choroidal neovascularization*

Tuberculosis (TB) is re-emerging as a global health problem. It is a slowly progressive, chronic, granulomatous infection caused by *Mycobacterium tuberculosis* (*MTB*). This acid-fast bacillus usually affects the lungs and other organs, including the cardiovascular system, gastrointestinal system, musculoskeletal system, genitourinary tract, central nervous system, skin, and eyes. The term of “ocular TB” describes an infection mostly by the *Mycobacterium tuberculosis* species that can affect any part of the eye (intraocular,

superficial, or surrounding the eye), with or without systemic involvement. “Secondary ocular TB” is defined as ocular involvement as a result of seeding by hematogenous spread from a distant site or direct invasion by contiguous spread from adjacent structures, like the sinus or cranial cavity.^{1,2}

Tuberculosis uveitis is a subject of renewed interest. In 1966, Duke-Elder stated that ocular tuberculosis (OTB) should be diagnosed in ‘cases of miliary or proliferative lesions in which there is no evidence of other disease liable to cause a

granulomatous uveitis and which exhibit tuberculous disease elsewhere, particularly if specific therapy induces a favourable response. Today, OTB in most cases still remains a presumptive, clinical diagnosis—not too far different from what was first described many years ago as we still do not have an ideal diagnostic test for OTB. In most cases, clinicians may only commit to ‘probable’ and ‘possible’ diagnoses of OTB in the presence of clinical signs and supportive investigations, in the absence of other possible causes of uveitis. The purpose of this review is to discuss the three main controversies of OTB today, with respect to the disease terminology, diagnostic challenges and dilemmas in management.^{3,4}

CASE PRESENTATION

A 17-year old female presented with vision loss in both eyes for 5 days before admission. There was an associated history of non-purulent cough. There was no history of systemic diseases. On examination the best corrected visual acuity (BCVA) was counting finger at 1 meters in the right eye, and BCVA was hand movement in the left eye. Slit lamp examination was unremarkable in both eyes. Fundus examination of both eyes showed a swollen disc of optic nerve and sub-retinal abscess in macula (figure 1). In the initial diagnosed with papil edema and chorioretinitis, The patient was hospitalized for three days, but she did not show improvement in vision and retina condition. Patient was referred to another ophthalmologist and diagnosis with posterior uveitis tuberculosis.

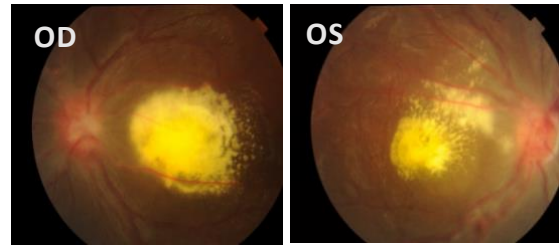


Fig 1. funduscopy before treatment shows swollen disc and subretinal abscess in the macula in both eyes

She was referred to pulmonologist to confirm the examination of systemic tuberculosis. Blood investigation showed erythrocyte sedimentation rate (ESR) is normal, tuberculin skin test was positive 11 mm, sputum test was negative for acid fast bacilli, chest x-ray was lungs active tuberculosis (figure 2). She started on four-drug regimen of anti-tuberculosis therapy; isoniazid (H), rifampicin (R), pyrazinamide (Z) and ethambutol (E) (2HRZE/4HR). After 2 months, the therapy with ATT did not improve on vision and condition of retina. The patient was administered with corticosteroid (methylprednisolone) by ophthalmologist. The starting dose given was 36 mg/day and tapered off every 7 days. Finally, maintenance doses were administered with 10 mg/day for 1 month. After 5 months of treatment with anti-tuberculosis and 3 months with corticosteroid, vision was progressive in both eyes showed BCVA in right eye 20/80 and BCVA in left eye counting finger at 3 meters, anti-tuberculosis treatment continued until 6 months.

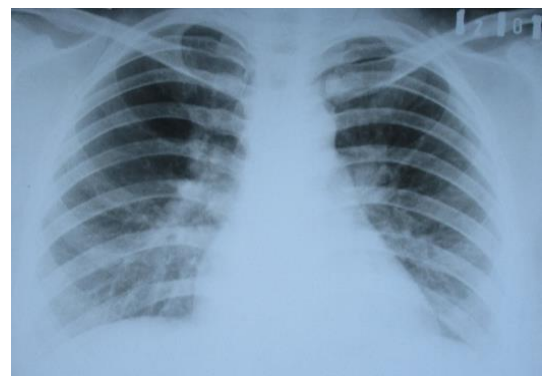

Fig 2. Chest x-ray lungs before treatment was active tuberculosis

After 6 months, the treatment with ATT and corticosteroid, the chest x-ray and sputum test showed negative result for tuberculosis (figure 3).

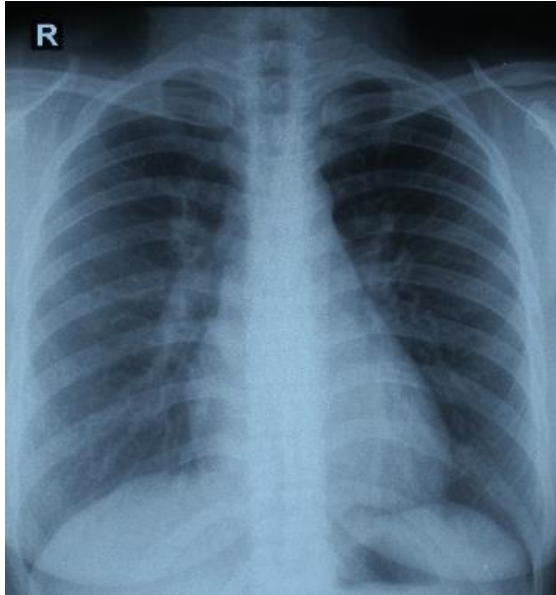


Fig 3. Chest X-Ray control after treatment was normal

The BCVA was 20/80 in the right eye and BCVA was counting finger at 1 meters in left eye. Fundus examination of the right eye result in occurrence of swollen disc on the optic nerve and decreased sub-retinal abscess in macula, however fundus examination of the left eye showed the appearance of swollen disc of optic nerve, and shows the worse condition with sub-retinal abscess and sub-retinal hemorrhages in the macula (figure 4)

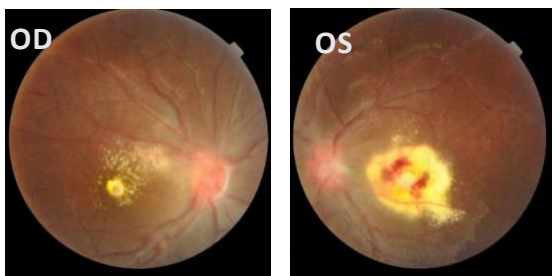

Fig 4. Funduscopy after treatment of the right eye showed swollen disc and constricted sub-retinal abscess in macula. Left eye showed swollen disc, sub-retinal abscess that came with sub-retinal hemorrhage

OCT of the right eye shows distorted central foveal anatomy, irregularities of RPE, and sub-retinal fluid. In the left eye shows absent contour of fovea, marked retinal thickening and elevation, sub-retinal fluid accumulation, irregularities of RPE and neurosensory retina. Both of the eyes showed abnormalities due to choroidal neovascularization (CNV) (Figure 5). Patient was then treated with intravitreal anti VEGF (bevacizumab), after 1 week after treatment BCVA in right eye was improved 20/50 but left eye showed no improvement in visual acuity and OCT (fig 6).

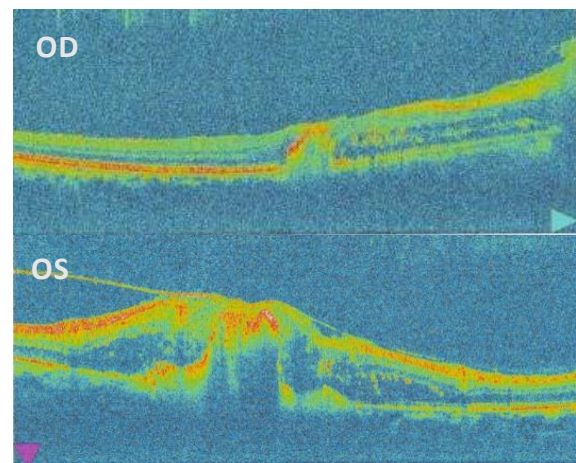


Fig 5. OCT before treatment shows choroidal neovascularization in both eyes

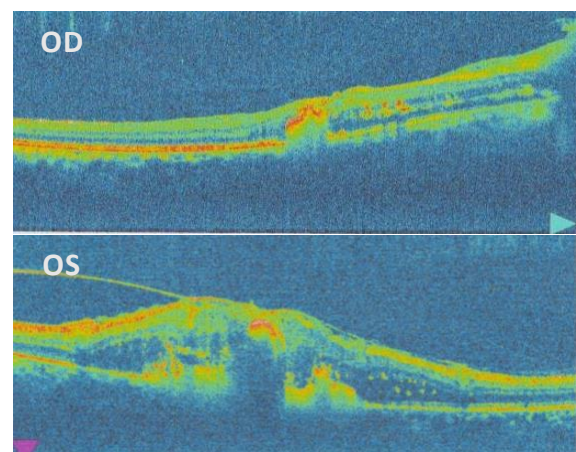


Fig 6. The OCT control have not shown different result after intravitreal Anti-VEGF

DISCUSSION

Tuberculosis (TB) is an infection caused by *Mycobacterium tuberculosis*, which can cause disease in multiple organs throughout the body, including the eye. The term “ocular TB” describes an infection by the *M. tuberculosis* species that can affect any part of the eye (intraocular, superficial, or surrounding the eye), with or without systemic involvement. “Secondary ocular TB” is defined as ocular involvement as a result of seeding by hematogenous spread from a distant site or direct invasion by contiguous spread from adjacent structures, like the sinus or cranial cavity.⁷

TB may affect the eye by direct invasion of the tubercle bacillus following hematogenous dissemination with local destruction and inflammation, or via a hypersensitivity reaction to the bacillus located elsewhere in the body. Ocular TB has several potential manifestations.^{1,7}

The diagnosis of TB-associated uveitis remains presumptive, supported by a positive tuberculin skin test (TST), lesions suggestive of pulmonary TB on chest x-ray (CXR) or evidence of an associate systemic TB infection. Recent developments such as interferon-gamma release assays (IGRAs) and PCR for detection of MTB DNA have been show to have lower sensitivities for TB-associated uveitis as compared with pulmonary TB.^{4,10}

There are currently no guidelines for the commencement or duration of anti-TB therapy (ATT) in patients with ocular tuberculosis (OTB). Whether OTB is a true infection of the eye or related to a systemic occult TB infection, at least it is known that ATT decreases the lifetime risk of developing active TB by 80%–90% in those with latent TB infections. Thus, it is believed that ATT could help eliminate the MTB inciting ocular inflammation either from within the eye or elsewhere in the body. Once the risks and benefits of initiating OTB have been weighed, the typical treatment regimen is to begin a combination of both systemic

corticosteroids and ATT, Patients received standard ATT according to Centers for Disease Control and Prevention (CDC) guidelines for a minimum of 6 months in total duration. This consisted of 2 months of four-drug therapy (isoniazid (H) 5 mg/kg daily, rifampicin (R) 450 mg daily, if body weight is <50 kg and 600 mg if the weight is >50 kg, pyrazinamide (Z) 30 mg/kg daily and ethambutol (E) 15 mg/kg daily) followed by a 4-month continuation phase (2HRZE/4HR). Patients receiving ATT were initially reviewed every 2 weeks for 8 weeks, then 2 to 3 monthly (or more frequently as required) to monitor response to therapy. Systemic corticosteroids were added if there was any increase in ocular inflammation after commencing ATT. In patients with posterior segment inflammation where ATT was not indicated, oral prednisolone was the systemic corticosteroid of choice, usually with a starting dosage of 1 mg/kg body weight.^{4,8,11}

As there are currently no guidelines on ATT duration, most patients with OTB receive 6 months of the standard regimen. However, a recent survey among ophthalmologists revealed a large variability in the duration of ATT or when therapy is discontinued in non-responders. One study even suggested that a longer duration of more than 9 months ATT is required for the treatment of OTB.⁴

In our patient, there was a response to anti tuberculosis therapy combined with oral corticosteroid and intravitreal anti-VEGF. After 6 month follow up the right eye shows good outcomes but only rare response in the left eye. Visual acuity in the right eye improved and sub-retinal abscess narrowed. In the left eye, the final vision was the same and the fundus appearance worsen in non-deteriorated sub-retinal recurrent abscess. Furthermore, it worsened in the presence of choroidal neovascularization.

Choroidal neovascularization (CNV) may lead to significant visual morbidity. When left untreated

Tuberculosis (TB) is overall an uncommon etiology for CNV, which is driven by vascular endothelial growth factor (VEGF). However, experimental animal models of intraocular TB reveal VEGF expression in the RPE, which has been shown to harbor *Mycobacterium tuberculosis* that thrive by inhibiting phagolysosome fusion. In the literature, most of clinical studies on inflammatory CNV therapy are case series with few underpowered retrospective studies often uncontrolled. Several therapeutic strategies have been attempted for uveitis related CNV: focal laser photocoagulation, photodynamic therapy with verteporfin, local and systemic corticosteroids, immunosuppression, surgery, and most recently intravitreal Anti-VEGF. Given the elevated VEGF levels associated with intraocular TB infections, anti-VEGF therapy may effectively suppress TB-related CNV.^{9,11}

Healing ocular tuberculosis is very difficult due to the unavailability of therapeutic guidelines. Meanwhile, this case is reported to highlight the fact that it is not essential pulmonary and extra pulmonary manifestation especially ocular involvement of tuberculosis may show the same response to ATT. This may be secondary to the fact that ocular hypoxia occurs very fast in eyes with inflammation of the choroid secondary to *mycobacterium tuberculosis*. This causes decreases choroidal circulation, and this may reduce the penetration of the drugs of ATT into the eye. However, if the therapy is not conducted immediately, the destructive structural anatomy of the eye may happen. Consequently, we need to be very careful and follow a case of intraocular tuberculosis at frequent intervals as there may be a very fast progression of ocular tuberculosis leading to a complete loss of the vision.⁶

CONCLUSION

The case highlights comprehensive combined modified to treat posterior uveitis tuberculosis and choroidal neovascularization. The patient was treated with anti-tuberculosis medications and oral corticosteroids, in addition to anti-VEGF injections. The appropriate treatment using the combination of systemic and intravitreal medication raised the opportunity for a better visual outcome among poor therapeutic guidelines and limited management of ocular tuberculosis. The patient examined in this report was treated by using oral corticosteroid treatment along the systemic tuberculosis medication and intravitreal Anti-VEGF. As a result, it showed good outcomes on her right eye but deteriorated on the other one.

REFERENCES

1. Ahmed M. Abu El-Asrar, Marwan Abouammoh, Hani S. Al-Mezaine, Tuberculosis uveitis, Middle East African Journal of Ophthalmology, Volume 16, Number 4, October-December 2009.
2. R. V. Paul Chan, MD, FACS, Weill Cornell Medical College, Ocular Tuberculosis (TB) – Asia Pacific. American Academy of Ophthalmology. 2016.
3. A.G. Vos, M.W.M. Wassenberg, J. de Hoog, J.J. Oosterheert. Diagnosis and treatment of tuberculous uveitis in a low endemic setting. International Journal of Infectious Diseases, published by Elsevier Ltd. 2013.
4. Marcus Ang, Soon-Phaik Chee. Controversies in ocular tuberculosis. Br J Ophthalmol 2017; 101:6–9.
5. Rupesh Agrawal, Bhaskar Gupta, Julio J. Gonzalez-Lopez, et al. The Role of Anti-Tubercular Therapy in Patients with Presumed Ocular Tuberculosis. Ocular Immunology & Inflammation, 2015; 23(1): 40–46.
6. Manisha Agarwal, Vivek Jha, Jyotirmay Biswas. Rapidly blinding posterior tubercular uveitis. Journal of Ophthalmic Inflammation and Infection 2014 4:13.
7. Russell W. Read, Nisha Acharya, Ralph D. Levinson. Tuberculosis. American Academy of Ophthalmology section 9. 2016-2017. P 344-353.
8. Si Thu Aung, Frank Bonsu, Jeremiah Chakaya, et al. Guidelines for treatment of drug-

- susceptible tuberculosis and patient care 2017 update. World Health Organization. 2017.
9. Enzo D'Ambrosio, Paolo Tortorella, Ludovico Iannetti. Management of Uveitis-Related Choroidal Neovascularization: From the Pathogenesis to the Therapy. Hindawi Publishing Corporation Journal of Ophthalmology Volume 2014.
 10. Marcus Ang MMed(Ophth), Alireza HedayatfarFRCSEd(Ophth), Rongli Zhang Mbiostat. Clinical signs of uveitis associated with latent tuberculosis. Clinical and Experimental Ophthalmology 2012.
 11. Esther Lee Kim, Damien C. Rodger, Narsing A. Rao. Case report Choroidal neovascularization secondary to tuberculosis: Presentation and management. Published by Elsevier. 2017.