

## Case Report

# Management of Penetrating Eye Injury with Intraocular Foreign Body

Andi Cleveriawan Arvi Putra, Andi Arus Victor, Elvioza, Ari Djatikusumo, Gita Lisa Andayani, Anggun Ramayundanta  
Department of Ophthalmology, Faculty of Medicine, University of Indonesia  
Cipto Mangunkusumo Hospital, Jakarta

## ABSTRACT

**Background:** To report the importance of vitrectomy procedure in penetrating eye injury with retain intraocular foreign body (IOFB) at the proper time.

**Methods:** An observational case report. A 17-year-old man came to hospital and was diagnosed as penetrating eye injury with retain intraocular foreign body of the left eye. The visual acuity of the left eye was only 2 meters finger counting. Immediate surgery of scleral buckling, vitrectomy, intraocular foreign body removal and intravitreal vancomycin-ceftazidime injection were performed on the next day.

**Results:** There were metallic IOFB, retinal vasculitis and focal retinitis seen when vitrectomy was performed. One month after vitrectomy, the visual acuity of the left eye has improved to 6/12 with correction.

**Conclusion:** Proper and prompt management of penetrating eye injury could contribute in preserving a good anatomical and functional result. In the existence of IOFB, vitrectomy should be done promptly in the first surgical window to gain a better result

**Keywords:** penetrating eye injury; intraocular foreign body

Penetrating eye injury is one of the most important cause of visual impairment.<sup>1</sup> The factors that associated with the risk of penetrating eye injury include age, sex, location of setting, and the use of goggles. High suspicion of IOFB should be kept in mind as it is associated with penetrating eye injury.<sup>2</sup> The incidence of penetrating ocular injury with IOFB from January to December 2009 in Cipto Mangunkusumo Hospital was 7 from 337 patients (2.07%).<sup>3</sup>

Endophthalmitis is a particularly devastating complication of posterior penetrating ocular trauma, and this intra-ocular infection occurred

between 2% and 48% of eyes with these injuries.<sup>4</sup> Risk factors for infection include retained intraocular foreign body, setting of injury, and delay in primary wound closure.<sup>5,6</sup> Recognition of early clinical signs of endophthalmitis, such as hypopyon, vitritis, or retinal periphlebitis, is important and early treatment is highly recommended.<sup>5,6</sup>

Comprehensive prophylactic antibiotic treatment at the time of injury repair and surgical intervention with vitrectomy and injection of intravitreal antibiotics when infection is suspected may significantly improve visual

acuity outcomes following penetrating injuries.<sup>6</sup> microsurgical and vitreoretinal instrumentation and techniques, allows managing the posterior segment injuries associated with IOFBs successfully.<sup>7</sup> It has been shown that vitreoretinal surgery is able to reduce the rate of visual loss. The properties and localization of the foreign body, interval between the injury and treatment, and primary ocular injuries associated with IOFB are known as the important prognostic factors.<sup>7-9</sup>

The purpose of this case is to report the importance to undergo vitrectomy in penetrating eye injury with IOFB at the proper time. In this case the sign of intra-ocular infection was found when vitrectomy was performed and showed significant improvement of visual acuity after the operation.

### CASE ILLUSTRATION

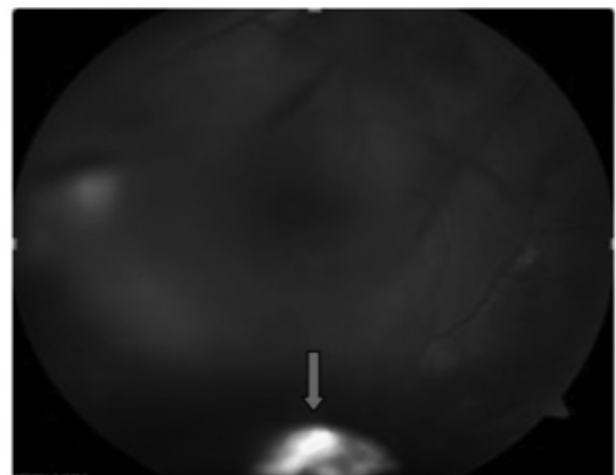
On 20 February 2014, a man, 17 years old, presenting with chief complain of blurred vision on his left eye since 4 days before admission (16/2/2014). His left eye was hit by fragment of rock while he was carving the wall and suddenly the vision got blurred. He also felt pain, redness, and watery of the eye. Patient decided to come to the nearest hospital (Persahabatan Hospital) and got toxoid injection, steroid eye drop, and then was referred to Cipto Mangun-kusumo Hospital.

The visual acuity of the left eye was 2 meters finger counting, the intraocular pressure was low on palpation. The eyelid was edema and spasms. There were conjunctival and ciliary injection and there was subconjunctival bleeding on the nasal side. The cornea was clear, anterior chamber was deep, cell +2, iris and pupil were round, central, and there was positive light reflect and consensual light reflect. The lens was clear but the vitreous was hazy due to bleeding. There was preretinal hemorrhage and intraocular foreign body/corpus alienum on inferior site of the macula at 2 cup disc distance at zone II at 6 o'clock position with preretinal hemorrhage. The visual acuity of the right eye was 6/6, the intraocular pressure was 14.0 mmHg, the other components were in normal condition.

The patient was diagnosed as penetrating eye injury with intraocular foreign body and vitreous hemorrhage of the left eye. Levofloxacin ED 6 times daily, and atropin sulphate eye drop 3 times daily was given to the left eye. Ciprofloxacin 500 mg 2 times daily and tranexamic acid 500

mg three times daily was given orally. The patient was planned to have scleral buckling, vitrectomy, intraocular foreign body removal, and intravitreal vancomycin (1 mg/0.1 ml)-ceftazidime (2.27 mg/0.1 ml) injection on the next day.

On 21 February 2014, scleral buckling, vitrectomy, intraocular foreign body removal, endolaser and intravitreal vancomycin-ceftazidime injection were done. The scleral rupture was shown at the superonasal position zone II at 7 o'clock position. At the time of operation, the retinal vasculitis and focal retinitis were shown at inferonasal. The location of foreign body was found at inferior at 6 o'clock position. A metallic foreign body was removed. Vitreous sample was also taken for culture and resistance test. The patient's left eye also had been given levofloxacin ED hourly, vancomycin fortified ED hourly, ceftazidime fortified ED hourly, prednisolone ED 3 times daily, and atropin sulphate ED 3 times daily, mefenamic acid 2 times daily, ciprofloxacin 2 times daily, and tranexamic acid 3 times daily for 5 days.



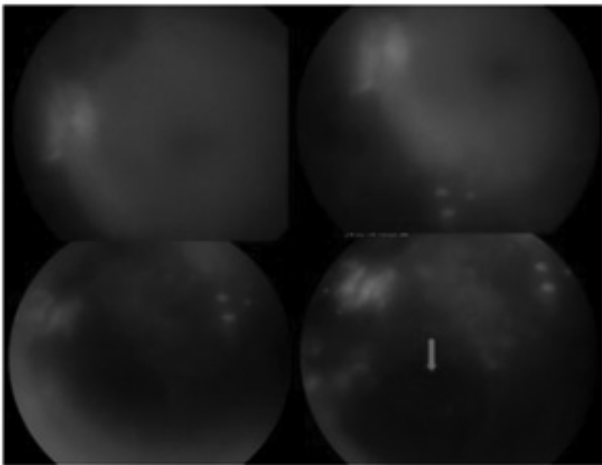
**Figure 1.** 4 days before admission, the vitreous was hazy, preretinal hemorrhage appeared at inferior and IOFB was present at zone II at 6 o'clock position.

One day after vitrectomy, the visual acuity of the left eye was 1 meter finger count. The intraocular pressure was normal per palpation. The eyelid was edema and spasm. There were conjunctival and ciliary injection. The cornea was clear and the anterior chamber was deep with +2 cells and fibrin. Iris, pupil, and the lens were in normal condition. The retina was attached and there was retinal hemorrhage at the inferior part of fundus, and there was focal

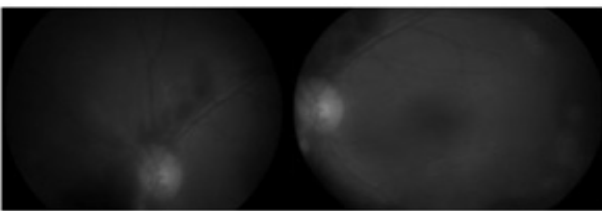
retinitis and sign of vasculitis. On 23 February 2014, the patient was allowed to go home and suggested to control in the next one week.

One week after vitrectomy, the visual acuity on the left eye was improved to 6/12 after correction with S-2.00. On funduscopy examination, there was preretinal hemorrhage at inferior of macula. Prednisolone and levofloxacin ED was given 6 times daily, atropin sulphate ED 3 times daily to the left eye. The patient was also given oral ciprofloxacin 500 mg 2 times daily and vitamin C 500 mg 3 times daily. The patient then was consulted to Infection and Immunology Division and decided to continue prednisolone ED, levofloxacin 6 times daily, and sulfas atrophin ED 3 times daily to the left eye, oral 750 mg ciprofloxacin 2 times daily, and suggested to come again in next one week.

Two weeks after vitrectomy, the visual acuity of the left eye was 6/12 with correction. The intraocular pressure of the left eye was normal. Prednisolone, levofloxa-cin, and atropin sulphate ED were given 3 times daily. Unfortunately, the vitreous culture was failed to grow and we couldn't get the result of resistance test.



**Figure 2.** 4 days after vitrectomy, the funduscopy presenting preretinal hemorrhage at inferior, and the retinal location of the intraocular foreign body



**Figure 3.** 1 week after vitrectomy, the clear imaging of funduscopy presenting preretinal hemorrhage at inferior and flame shape hemorrhage at superior

One month after vitrectomy, the visual acuity on the left eye was still 6/12 with correction, the intraocular pressure on the left eye was 25.0 mmHg. The patient was given prednisolone, levofloxacin ED 4 times on the left eye, and advised to come in the next 1 week. Unfortunately, the patient didn't come on the next other control.

## DISCUSSION

Penetrating eye injury is quite a common presentation in the emergency room and it is an important cause of ocular morbidity.<sup>10</sup> Dannenberg et al<sup>11</sup>, reported that between 1985 and 1991, there were 635 (22%) work-related penetrating eye injuries among the 2939 cases. Important assessment of the damage which includes setting of injury, initial visual acuity, and location of the wound.<sup>12</sup> High suspicion of IOFB should be kept in mind as it is associated with globe ruptures.<sup>2</sup>

Parver et al<sup>1</sup>, Parver et al, reporting among 2939 case of penetrating eye injury 83% were male and the mean age was 29.2. In this case the patient was male and the age was 17. He also reporting the settings of injuries were occurred the home 28%, the worksite 21%, at recreation 11%, and in transportation 8%. The setting of injury were related to the consumption of alcohol and the usage of safety goggles. At the time of the injury, only 1.5 percent of all injured persons were wearing safety goggles. In this case the patient had the risk factor. The patient also didn't wear a safety goggles at the time of accident and the location of scleral rupture was at the superonasal position zone II at 7 o'clock position.

Schmit et al<sup>10</sup> reported, that 214 patients came with open globe injury. About 15% of the patient with IOFB had visual survival (visual acuity more than light perception) and 2,3% were not gain visual survival (no light perception, underwent evisceration and enucleation).

Coleman<sup>13,14</sup> described 3 windows for surgical intervention: "The first window occurs after injury, but before the development of inflammatory sequelae. At this point, removing the entire vitreous is generally unnecessary. Only the disrupted lens, blood, and vitreous must be

removed". The argument for early vitrectomy is to remove all proinflammatory factors before fibrosis initiate. The counterargument is that operating on an acutely traumatized eye can have unpredictable findings with higher likelihood of continued hemorrhage. Choroidal hemorrhages also have not undergone liquefaction, making drainage difficult. Vitrectomy is also more challenging because a spontaneous PVD usually has not formed yet during this first window, especially in young patients.

The second window is from 7 to 14 days. "Once the inflammation is controlled or the originally lacerated vessels have healed, or both, a second window appears before the full development of organized fibro-proliferative membranes". The membranes are still easy to peel and cut during this phase, and traction, if any, can be relieved without much difficulty. A PVD would have usually formed by this window, which facilitates the vitrectomy. However, a lack of a PVD should not deter one from proceeding with the vitrectomy. The vitreous does need to be completely removed by this stage. Waiting for this period after the primary repair also allows a more thorough examination with ultrasonography to determine whether the eye is salvageable based on the intraocular anatomic status. Almost all vitreoretinal surgeons typically wait for this 7- to 14-day window.

"A third window often occurs if and when the acute hemorrhagic and inflammatory stages have subsided. Surgery is then indicated primarily for optical reasons, that is, providing an opening in the anterior cyclitic structure or posterior vitreous hyaloid complex or both". Fibrovascular proliferation and panophthalmic sequelae of inflammation have often created tractional changes by this stage. This third window may be narrow, and should be avoided if possible, as the patient is at risk for tractional retinal detachment and retinal tears while waiting for surgery.

In this case presentation vitrectomy was done in the first surgical window because there was IOFB in this traumatic eye. Prompt vitrectomy was done to prevent the possibility of the occurrence of intraocular infection or endophthalmitis. After vitrectomy, the visual acuity was raised from two meter finger counting to 6/12. The most common cause of poor visual results in cases of retained IOFB is

the retinal damage sustained at the time of IOFB entry, tractional complications of posterior segment, siderosis, and postoperative retinal detachment. Preoperative retinal detachment, the location and the size of IOFB, scleral or corneoscleral entry wound have predictive role of a post operative retinal detachment.

The presence of an IOFB will increase the incidence of endophthalmitis.<sup>4</sup> The incidence of open globe injuries associated endophthalmitis without IOFB can range between 3.1% and 30% of eyes. If an IOFB is present, the incidence ranges from 1.3% to 60%.<sup>6</sup> Zhang et al<sup>15</sup> reported, from 1421 eyes of all open-globe injuries, IOFBs were present 28.60% and endophthalmitis developed in 232 (16.76%). In this case the patient was not diagnosed as endophthalmitis because there were no sign of infection in the eye. The sign of infection such as vasculitis and focal retinitis that had already happened on 5 days after initial trauma was known at the time of vitrectomy. The interval between the injury and primary surgical repair was critical in predicting the risk of infectious endophthalmitis. A delay in primary repair of the ruptured globe of more than 24 hours was associated with increased risk of infectious endophthalmitis. Thompson et al<sup>16</sup> reported, infectious endophthalmitis developed in 10 (3.5%) of 287 eyes repaired within 24 hours compared with 22 (13.4%) of 164 eyes repaired more than 24 hours after the penetrating injury.

Approximately 75% of all post-traumatic culture-positive endophthalmitis cases are infected by Gram-positive organisms.<sup>17</sup> Thompson et al<sup>16</sup> also reported the risk of infectious endophthalmitis developing for metallic was 29 (7.2%) of 401 eyes with metallic foreign body, nonmetallic 3 eyes (6.8%) of 44 nonmetallic eyes, and 1 eyes (5.9%) of 177 organic intraocular foreign bodies. In this case the intraocular foreign body was a metallic. But unfortunately the culture for vitreous sample was not grown and couldn't have the result of resistance test. Thompson<sup>16</sup> also reported positive vitreous sample cultures were obtained in 22 (65%) of 34 eyes. Bacillus species were the sole isolate in 8 (36%) of 22 eyes, 10 cultures grew Staphylococcus species alone (45%), Streptococcus was identified in one eye (5%) and three eyes (14%) had mixed flora.



When treating a patient suspected with traumatic endophthalmitis, the antibiotics agent should cover Gram-positive and Gram-negative organisms.<sup>18,19</sup> Especially in cases where the suspicion of post-traumatic endophthalmitis is high, Thompson et al<sup>16</sup> recommended starting initially with intra-venous vancomycin (1 gram every 12 hours) and ceftazidime (1 gram every 8 hours) along with topical fortified vancomycin (50 mg/mL) and ceftazidime (50-100 mg/mL) everyhour. Many author also recommend intravitreal vancomycin (1 mg/0.1 mL) and ceftazidime (2.25 mg/0.1mL) unless the patient is allergic to the medication.<sup>18,20</sup> In this case the patient had intravitreal antibiotics vancomycin (1 mg/0.1 mL) and ceftazidime (2.27 mg/0.1mL), the patient was also given fortified vancomycin and ceftazidime after the vitrectomy.

The patient was also given ciprofloxacin orally and topical levofloxacin due to prophylaxis of infection. The fluoroquinolone agent such as levofloxacin, ciprofloxacin, gatifloxacin and moxifloxacin are used in the prophylactic treatment of endophthalmitis. Moxifloxacin has better coverage against Gram positive organisms and anaerobes than ciprofloxacin, but ciprofloxacin has better coverage against *Pseudomonas* species as well as *Enterobacteriaceae*.<sup>20,21</sup> Two doses of oral levo-floxacin (500 mg 12 hours apart) a day can be detected in the vitreous of an uninflamed phakic eye after only 2.5 hours.<sup>18</sup>

## CONCLUSION

Proper and prompt management of penetrating injury may contribute to give a good anatomical and functional result. In the existence of IOFB, vitrectomy should be done promptly in the first surgical window to gain a better result.

## REFERENCES

1. Parver LM, Dannenberg AL, Blacklow B, Fowler CJ, Brechner RJ, Tielsch JM. Characteristics and causes of penetrating eye injuries reported to the National Eye Trauma System Registry, 1985-91. Public health reports (Washington, DC : 1974). 1993;108(5):625-32.
2. De Juan E, Jr., Sternberg P, Jr., Michels RG. Penetrating ocular injuries. Types of injuries and visual results. *Ophthalmology*. 1983;90(11):1318-22.
3. Yuriani I. characteristics of traumatic ocular injury cases at emergency unit of dr. cipto mangunkusumo hospital jakarta January - December 2009. Jakarta: universitas indonesia; 2011.
4. Ryan SJ, Yoon YH. Posterior Segment Trauma: Open Globe. In: ryan sj, editor. *Retina* (Philadelphia, Pa). 3. Philadelphia: elsevier; 2006. p. 2353-63.
5. Reynolds DS, Flynn HW, Jr. Endophthalmitis after penetrating ocular trauma. *Current opinion in ophthalmology*. 1997;8(3):32-8.
6. Bhagat N, Nagori S, Zarbin M. Post-traumatic Infectious Endophthalmitis. *Survey of ophthalmology*. 2011;56(3):214-51.
7. Falavarjani KG, Hashemi M, Modarres M, Parvaresh MM, Naseripour M, Nazari H, et al. Vitrectomy for posterior segment intraocular foreign bodies, visual and anatomical outcomes. *Middle East African journal of ophthalmology*. 2013;20(3):244-7.
8. Chaudhry IA, Shamsi FA, Al-Harhi E, Al-Theeb A, Elzaridi E, Riley FC. Incidence and visual outcome of endophthalmitis associated with intraocular foreign bodies. *Graefe's archive = Albrecht von Graefes Archiv fur klinische und experimentelle Ophthalmologie*. 2008;246(2):181-6.
9. Mieler WF, Mittra RA. The role and timing of pars plana vitrectomy in penetrating ocular trauma. *Arch Ophthalmol*. 1997;115(9):1191-2.
10. Schmidt GW, Broman AT, Hindman HB, Grant MP. Vision survival after open globe injury predicted by classification and regression tree analysis. *Ophthalmology*. 2008;115(1):202-9.
11. Dannenberg AL, Parver LM, Brechner RJ, Khoo L. Penetrating eye injuries in the workplace: The national eye trauma system registry. *Archives of Ophthalmology*. 1992;110(6):843
12. Pieramici DJ, Sternberg P, Jr., Aaberg TM, Sr., Bridges WZ, Jr., Capone A, Jr., Cardillo JA, et al. A system for classifying mechanical injuries of the eye (globe). The Ocular Trauma Classification Group. *American journal of ophthalmology*. 1997;123(6):820-31.
13. Gregor Z, Ryan SJ. Combined posterior contusion and penetrating injury in the pig eye. III. A controlled treatment trial of vitrectomy. *The British journal of ophthalmology*. 1983;67(5):282-5.
14. Michels RG. Vitrectomy Methods in Penetrating Ocular Trauma. *Ophthalmology: Journal of the AAO*. 87(7):629-45.
15. Zhang Y, Zhang M, Jiang C, Qiu HY. Intraocular foreign bodies in china: clinical characteristics, prognostic factors, and visual outcomes in 1,421 eyes. *American journal of ophthalmology*. 2011;152(1):66-73. e1.
16. Thompson JT, Parver LM, Enger CL, Mieler WF, Liggett PE. Infectious endophthalmitis after penetrating injuries with retained intraocular foreign bodies. *National Eye Trauma System*. *Ophthalmology*. 1993;100(10):1468-74.
17. Alfaro DV, Roth D, Liggett PE. Posttraumatic endophthalmitis. Causative organisms, treatment, and prevention. *Retina* (Philadelphia, Pa). 1994;14(3):206-11.
18. Kresloff MS, Castellarin AA, Zarbin MA. Endophthalmitis. *Survey of ophthalmology*. 43(3):193-224.
19. Gentile RC, Shukla S, Shah M, Ritterband DC, Engelbert M, Davis A, et al. Microbiological Spectrum and Antibiotic Sensitivity in Endophthalmitis: A 25-Year Review. *Ophthalmology*. 2014.
20. Ukpo GE, Ebuehi OA, Kareem AA. Evaluation of Moxifloxacin-induced Biochemical Changes in Mice. *Indian journal of pharmaceutical sciences*. 2012;74(5):454-7.
21. Iyer MN, He F, Wensel TG, Mieler WF, Benz MS, Holz ER. Intravitreal clearance of moxifloxacin. *Transactions of the American Ophthalmological Society*. 2005;103:76-81; discussion -3.